

# Imaging of Osteochondromas Suspected of Malignant Transformation

KUMAR VENU MADHAV RAMAVATHU, SWAPNDEEP SINGH ATWAL, U.C.GARGA

## ABSTRACT

Osteochondroma is regarded as the most common benign osseous neoplasm, which is a developmental anomaly, rather than a true neoplasm. Findings such as increase in size of a previously stable osteochondroma, irregular or indistinct margins, development of areas of lysis or erosions, or a soft tissue mass with or without foci of calcifications on

radiography or Computed Tomography (CT) are suggestive of malignant transformation. Magnetic Resonance Imaging (MRI) is useful in demonstrating pressure effects on adjacent soft tissues and in detection and characterization of cartilaginous cap, which when measures more than 2cm in thickness is highly suggestive of malignant transformation.

**Keywords:** Bone, Cartilaginous cap, Exostosis, Malignant tumour

## INTRODUCTION

Osteochondroma is the most common benign osseous neoplasm. It may occur as a single or multiple lesions, the latter as a hereditary syndrome [1].

It represents 10-15% of all osseous neoplasms and 50% of all benign lesions. It is a developmental anomaly rather than a true neoplasm. The lesion comprises of cortical and medullary bone, which is in direct continuity with the parent bone and is covered by a hyaline cartilaginous cap. The age of presentation may be anywhere from 2 to 60 years, but the most common age at presentation is 11-20 years [2]. There is no sex predilection in case of solitary osteochondromas. However, Hereditary Multiple Exostosis (HMO) syndrome commonly affects males than females and Caucasians are the most common race affected, approximately 0.9-2 individuals per 100,000 of population. 65% of the affected individuals have family members with autosomal dominant transmission of HMO genes [3]. The long bones around the knee joint are most common sites of involvement. Among flat bones, ilium and scapula are commonly involved.

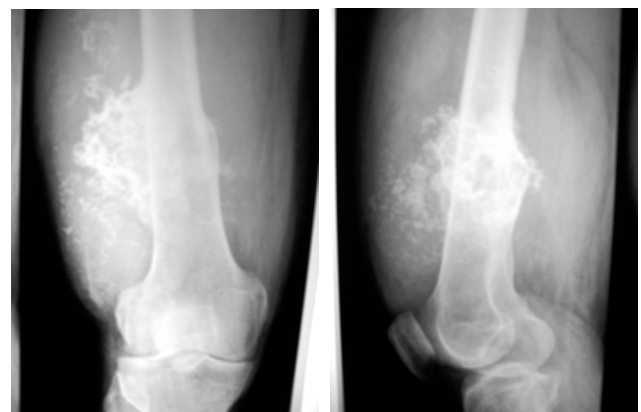
The common complications include cosmetic or osseous deformity, fracture, neurovascular compromise, bursaformation and malignant transformation [4]. Malignant transformation is the most serious and feared complication, occurring in approximately 1% of the solitary lesions and 3-5% of cases of HME. Chondrosarcoma arising from the cartilaginous cap is the reason for malignant transformation. Pain, swelling and enlargement of osteochondromas after skeletal maturity must be viewed with suspicion [5,6]. In majority of cases there is

development of secondary chondrosarcoma, however rare cases of secondary osteosarcoma have been reported [7]. Malignant degeneration of osteochondromas comprise of 8% of all chondrosarcomas.

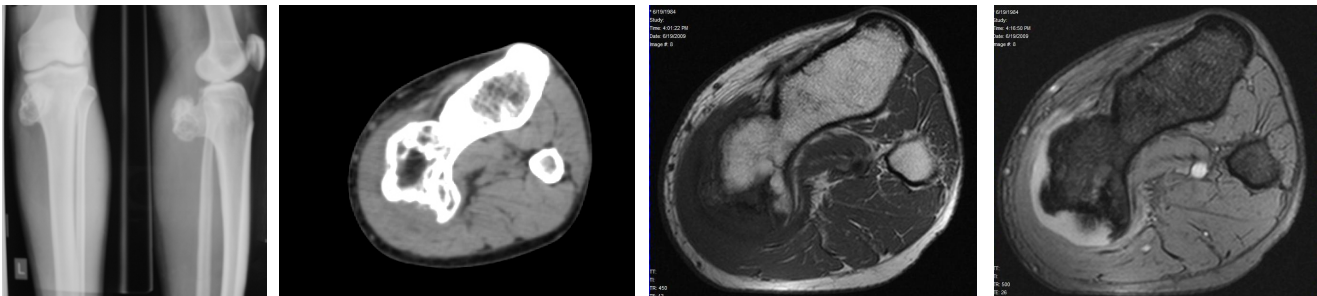
**Radiological features [Table/Fig-1]:** Radiographic features include increase in size of a previously stable osteochondroma

Thick, bulky cartilaginous cap (>2 cm).
Development of a soft tissue mass with or without soft tissue calcifications.
Dispersed calcifications within the cartilaginous cap.
Bone destruction.
Altered appearance on sequential studies.

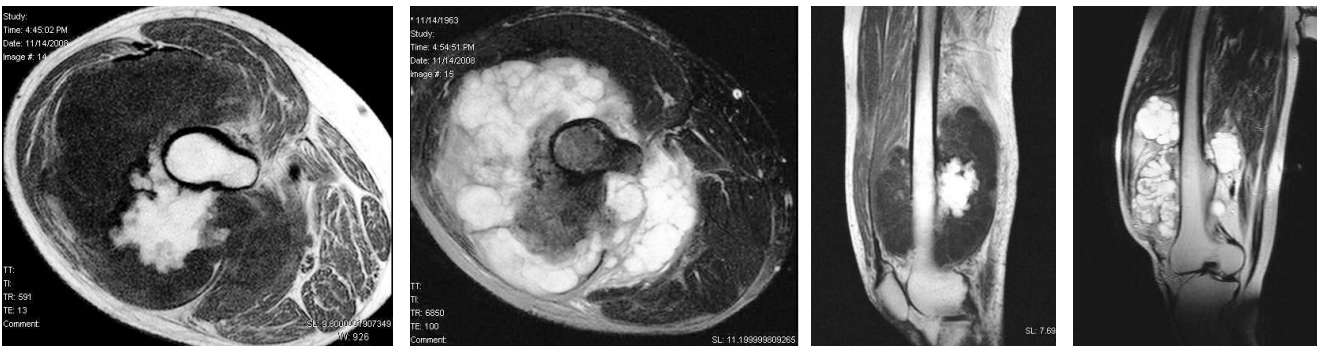
**[Table/Fig-1]:** Radiological features of malignant transformation



**[Table/Fig-2]:** Plain radiographs (A,B) in frontal and lateral views showing the bony exostosis with multiple calcifications and soft tissue swelling



**[Table/Fig-3]:** Plain radiographs showing osteochondroma arising from the posterior surface of proximal tibia (A), CT shows the exostosis surrounded by a hypodense cartilaginous cap (B). T1w spin echo and T2 gradient axial images (C,D) showing the bony exostosis and a 10mm thick cartilaginous cap, which is hypointense on T1 and hyperintense on T2W images



**[Table/Fig-4]:** T1W and T2W axial images (A,B) showing the bony exostosis surrounded by a 6cm thick, multilobulated cartilaginous cap seen as an area of high signal on T2W images, suggestive of malignant degeneration. Sagittal and coronal (C,D) images showing the full extent of the exostosis and the cartilaginous cap

in a patient with mature skeleton, irregular or indistinct margins, development of areas of lysis or erosions within the lesion, development of a surrounding soft tissue mass with or without foci of calcifications [Table/Fig-2].

Computed tomography is useful in detection of the lesion, its extent, soft tissue evaluation and has the advantage of superior detection of small fractures, fine calcific foci. It is also useful in detection of the cartilaginous cap, most prominently the mineralized portion of it [4,8]. However, some studies revealed that Computed Tomography (CT) is not reliable in depicting cartilaginous caps measuring less than 2.5 cms [9]. Though ultrasonography can be used for measuring cartilage thickness, it is operator dependent and has poor sensitivity in obese patients and suboptimal utility in evaluating osseous structures [10].

Magnetic Resonance Imaging (MRI) is useful in demonstrating the continuity between the lesion and the native bone. The osseous cortex remains hypointense on pulse sequences and the signal intensity of medulla corresponds to that of yellow marrow [3]. MRI is considered to be the best imaging modality in diagnosing malignant transformation. It detects the pressure effects of the exostosis on adjacent soft tissues because of its superior soft tissue contrast [Table/Fig-3]. Compared to the other modalities discussed above, MRI is most accurate in demonstrating the characteristics of the hyaline cartilaginous cap [11] [Table/Fig-3].

The mineralized foci of the cartilaginous cap remain hypointense on both T1 and T2W sequences, whereas the unmineralized portions because of their high water content appear hypointense on T1W and hyperintense on T2W images [12] [Table/Fig-4]. On post gadolinium images, nodular enhancement of the tumour may be seen [13]. Cartilage cap less than 1cm is considered to be benign, whereas more than 2cm is malignant in nature and must be recommended for resection [Table/Fig-4]. Using 2cm as cut off for differentiating benign from malignant osteochondromas, the sensitivity and specificity for MR imaging was found to be 100 and 98% [14]. Poor visualization of soft tissue calcifications when compared to CT is a known drawback of MRI.

Osteochondromas, especially multiple and hereditary must be on a regular follow-up for malignant transformation. Surgery is the treatment of choice once malignancy is confirmed [15].

## CONCLUSION

Osteochondroma is regarded as the most common benign osseous neoplasm and its malignant transformation is considered to be the most serious and feared complication. Plain radiograph and CT are helpful in confirming the presence of osteochondroma and are useful in giving an indication of its extent and signs of probable malignant transformation. MRI is considered to be the best imaging modality in diagnosing malignant transformation. It detects pressure effects of the

exostosis on adjacent soft tissues. Osteochondroma with cartilaginous cap of thickness more than 2cm confirms malignant transformation and must be recommended for resection.

## REFERENCES

- [1] Liesbeth H, Judith V.M.G.B., Antonie H.M.T., Herman M. K., Pancras C.W.H. Multiple Osteochondromas: Clinicopathological and Genetic Spectrum and Suggestions for Clinical Management; Hereditary. *Cancer in Clinical Practice*. 2004; 2(4):161-73.
- [2] Adam A, Dixon A, Grainger R, Allison D. Grainger & Allison's diagnostic radiology. Philadelphia, PA: Churchill Livingstone/Elsevier; 2008: 1037-39.
- [3] Kitsoulis P, Galani V, Stefanaki K, Paraskevas G, Karatzias G, Agnantis N et al. Osteochondromas: review of the clinical, radiological and pathological features. *In vivo*. 2008;22(5):633-46.
- [4] Panagiotis K, Vassiliki G, Kalliopi S, Georgios P, Georgios K, Niki JA et al. Osteochondromas: Review of the Clinical, Radiological and Pathological Features. *In vivo*. 2008; 22: 633-46.
- [5] Marco CP, Elena FM, Begoña GSJ, Slavina MM. Osteochondroma: radiological diagnosis, complications and variants. *Revista Chilena de Radiología* 2013; 19(2):73-81.
- [6] Gregory AS, Douglas SH, Joe R, Ernest UC. Malignant progression in two children with multiple osteochondromas. *Sarcoma*. 2010(2010): 1-7.
- [7] Engel E, Noogueira BM, Brassesco M, Silva G, Valera E, Peria F, Motta T, Tone L. Osteosarcoma arising from osteochondroma of the tibia: Case report and cytogenetic findings. *Genet Mol Res*. 2010; 11(1):448-54.
- [8] Krieg JC, Buckwalter JA, Peterson KK, El Khoury GY, Robinson RA. Extensive growth of an osteochondroma in a skeletally mature patient: a case report. *J Bone Joint Surg Am*. 1995; 77:269-73.
- [9] Hudson TM, Springfield DS, Spanier SS, Enneking WF, Hamlin DJ. Benign exostoses and exostotic chondrosarcomas: evaluation of cartilage thickness by CT. *Radiology*. 1984; 152:595-99.
- [10] Nojima T, Yamashiro K, Fujita M, Isu K, Ubayama Y, Yamawaki S. A case of osteosarcoma arising in a solitary osteochondroma. *Acta Orthop Scand*. 1991; 62:290-92.
- [11] Young CL, Sim FH, Unni KK, McLeod RA. Chondrosarcoma of bone in children. *Cancer*. 1990; 66:1641-48.
- [12] Hillmann A, Sebastian B, Thomas L, Winfred W. Multicentric malignant transformation of multiple exostoses. *Skeletal Radiology*. 1998; 27:233-36.
- [13] Geirnaerd MJ, Bloem JL, Eulderink F, Hogendoorn PC, Taminiu AH. Cartilaginous tumors: correlation of gadolinium-enhanced MR imaging and histopathologic findings. *Radiology*. 1993;186:813-17.
- [14] Stephanie AB, Mark DM, Donald JF, Mark JK. Improved differentiation of benign osteochondromas from secondary osteochondromas with standardized measurement of cartilage cap at CT and MR imaging. *Radiology*. 2010;255:857-65.
- [15] Volk S, Wagener G, Zaharie D. Secondary chondrosarcoma: Malignant transformation of pre-existing hereditary and non-hereditary cartilaginous lesions. *South African Journal of Radiology*. (2014); 18(2):1-5.

### AUTHOR(S):

1. Dr. Kumar Venu Madhav Ramavathu
2. Dr. Swapndeeep Singh Atwal
3. Dr. U.C.Garga

### PARTICULARS OF CONTRIBUTORS:

1. Resident Physician, Department of Radiology, Alexandra Hospital, Singapore.
2. Senior Resident, Department of Radiodiagnosis, PGIMER and Dr. Ram Manohar Lohia Hospital, New Delhi, India.
3. Professor and Head, Department of Radiodiagnosis, PGIMER and Dr. Ram Manohar Lohia Hospital, New Delhi, India.

### NAME, ADDRESS, E-MAIL ID OF THE CORRESPONDING AUTHOR:

Dr. Swapndeeep Singh Atwal  
8/4, 3<sup>rd</sup> Floor, Old Rajender Nagar,  
New Delhi-110060, India.  
E-mail: swapndeepsinghatwal@gmail.com

### FINANCIAL OR OTHER COMPETING INTERESTS:

None.

Date of Publishing: Apr 10, 2015