

Submental Intubation: A Simple Route of Intubation for Complex Maxillofacial Trauma

KUMAR NILESH, NEELIMA A MALIK, PANKAJ PATIL, NILESH PATIL, SHAMBHVI MALIK, MAYURI JOBANPUTRA

ABSTRACT

Purpose: The aim of the study was to evaluate the use of submental route of intubation for maxillofacial trauma patient, in whom oral and nasal routes of intubation were contraindicated.

Achieving a secure airway is of utmost importance in patients under general anaesthesia. The two most common methods of airway management (intubation) in such patients include oro-tracheal and naso-tracheal intubation. However, both may be contraindicated in complex maxillofacial trauma, like pan-facial fractures requiring surgical access to oral and nasal cavity in the same surgery. Traditionally the only other alternative available in such case is tracheostomy, which is associated with high risk of iatrogenic complications. This work presents our current experience of airway management using submental intubation in such situations. Frequency, indications, steps and outcome of the technique are discussed in details.

Materials and Methods: Patients treated at Krishna hospital, Karad, Maharashtra, India from August 2011 to September

2014, for facial bone fracture under general anaesthesia, in whom both oral and nasal route of intubation was contraindicated, were chosen for submental intubation. Data pertaining to demographics, classification of fracture, time required for intubation and intra-operative & post-operative complication associated with submental route of intubation were recorded.

Results: Out of 252 patients of maxillofacial trauma treated under general anaesthesia, 41 patients underwent submental intubation. Submental intubation allowed simultaneous management of all the fractures (Nasal as well as jaw fractures) and establishment of dental occlusion without any interference with the endotracheal tube. The procedure was simple to execute with no intra-operative complication. Only one patient presented with transient mild lingual haematoma post-operatively, which resolved spontaneously.

Conclusion: Submental intubation is an attractive and viable alternative to tracheostomy in selected patients with multiple facial bone fracture.

Keywords: Airway management, Anaesthesia, Fracture, Tracheostomy

INTRODUCTION


Orotracheal Intubation (OTI) is a standard way of securing airway in patients under general anaesthesia. The possibility to establish or repeatedly check dental occlusion intraoperatively rules out its use in patients with dentate jaw fractures [1]. Nasotracheal Intubation (NTI) can be used in these patients as it allows establishment of occlusion and maxillomandibular Fixation (MMF) without interfering with intraoral surgical approach. Presence of jaw fractures along with fracture of nasal pyramid or anterior cranial base contraindicates use of NTI, as it interferes with the surgical site. NTI is also not used in order to avoid complications like CSF rhinorrhoea, meningitis and communication of nasal cavity with cranial fossa [2]. Conventionally tracheostomy is the most favoured option for securing surgical airway in such situation. However tracheostomy is associated with significant risk of iatrogenic

complications [3,4].

Submental Intubation (SMI) was first described by Francisco Hernandez Altemirin in 1986 as an alternative to tracheostomy in severe maxillofacial trauma patients [5]. It consists of diverting the proximal end of an oro-tracheal tube through the floor of the mouth and submental region, which allows free intraoperative access to the dental occlusion and nasal pyramid. This paper presents our current experience of airway management using submental intubation in complex maxillofacial trauma. Frequency, indications, steps and outcome of the technique are discussed in details.

MATERIALS AND METHODS

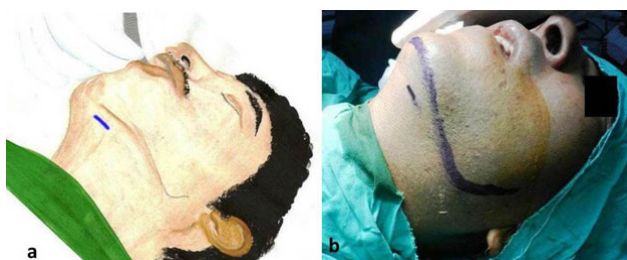Medical records of all the patients treated for facial bone fracture under general anaesthesia, from August 2011 to September 2014 was analysed. Out of 252 patients who



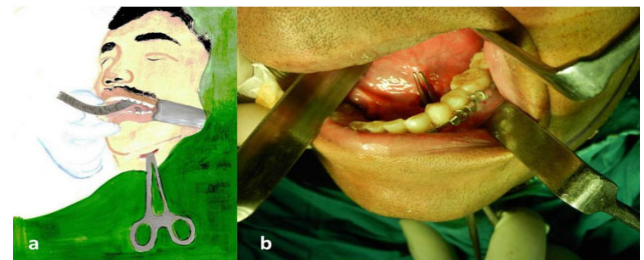
[Table/Fig-1]: Armoured flexometallic endotracheal tube with connector detached

underwent open reduction and fixation of various facial bone and jaw fracture during this period, 157 patients were managed by nasotracheal intubation, 53 by orotracheal intubation, while one patient required tracheostomy. Forty one patients underwent submental intubation. Data pertaining to demographics, classification of fracture, intra-operative variable and intra-operative & post-operative complication associated with submental route of intubation was recorded.

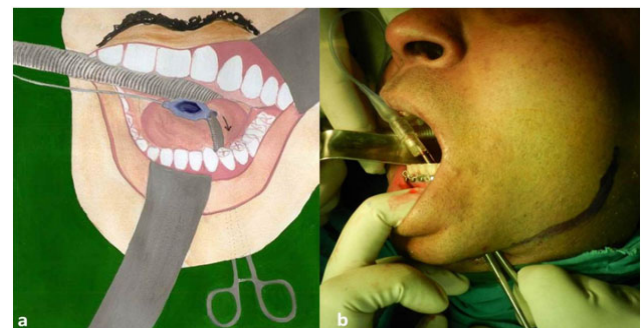
Surgical technique of submental intubation: Routine orotracheal intubation was done using flexometallic armoured endotracheal tube with detachable connector [Table/Fig-1]. Throat pack was placed using sterile moist ribbon gauge to secure the airway from pharyngeal secretions and bleeding from planned submental approach. The skin over the submental-submandibular area was prepared with aqueous providone iodine (betadine) and temporary draping was done. A 1.5-2 cm incision was placed over skin in submental region either at midline or slightly off the midline, directly adjacent to the lower border of the mandible [Table/Fig-2a,b]. The later was preferred for most of the cases as a para-median approach avoided piercing through the anterior belly of diaphragm and genioglossus muscles present in midline. Blunt dissection with long curved haemostat was done through, subcutaneous layer, platysma, deep fascia and mylohyoid muscle to reach mucosa overlying floor of the mouth. The dissection was kept close to the lingual surface of the mandible as the haemostat advances superiorly to oral cavity. The mucosa over floor of



[Table/Fig-2]: Diagrammatic Illustration (a) and clinical photograph (b) paramedian incision in submental region



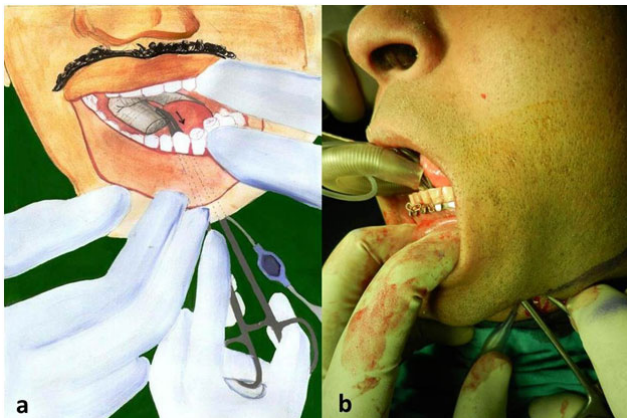[Table/Fig-3]: Diagrammatic Illustration (a) and clinical photograph (b) of the tip of the haemostat maneuvered by blunt dissection onto the floor of the mouth, keeping it anteriolateral to the submandibular duct opening



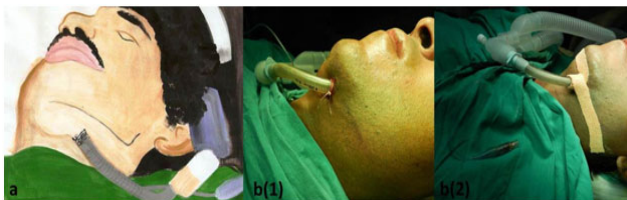[Table/Fig-4]: Diagrammatic Illustration (a) and clinical photograph (b) showing the pilot cuff with deflated balloon grasped by tip of haemostat, ready to be pulled through the submental tunnel onto the submento-submandibular region

the mouth was penetrated with tip of the haemostat at about midpoint between sublingual caruncle and medial mandible border, keeping it anteriolateral to the submandibular duct opening [Table/Fig-3a,b]. The submental tunnel was further enlarged by opening up the beaks of the haemostat so as to allow sufficient space for passage of the ET tube. A guide to this was the submental tunnel should allow passing of gloved index finger of the surgeon from skin to the oral cavity.

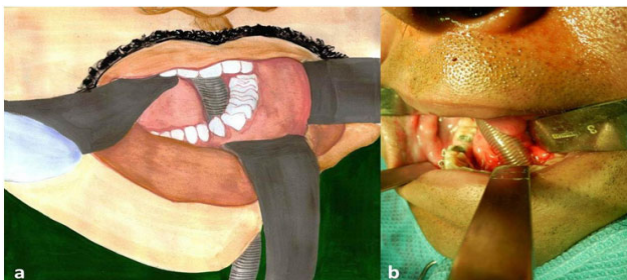
Once the submental passage was established, the cuff of the ET tube was deflated. The pilot tube with balloon was held securely by the distal end of haemostat and gently pulled through the submental tunnel [Table/Fig-4a,b]. Then the ET tube was disconnected from the breathing circuit and the connector removed. The edge of the ET tube was grasped between haemostat beaks and exteriorized by gently maneuvering it from floor of the mouth through the submental tunnel to the submental region [Table/Fig-5a,b]. High concentration of inspired oxygen was given prior to shifting the tube from oral to submental route, to decrease the risk of desaturation due to transient disconnection of oxygen supply. Once the distal end of the ET was exteriorized, the connector was reattached and ET tube was connected to the circuit. The cuff was inflated with about 10 mL of air. To make sure that the tube was not displaced during its passage through the submental tunnel, the position of the tube was checked with regard to the teeth before and after submental procedure. The



[Table/Fig-5]: Diagrammatic Illustration (a) and clinical photograph (b) of the Endotracheal tube (with connector removed), grasped by reinserted haemostat, ready to be exteriorized through the submental tunnel



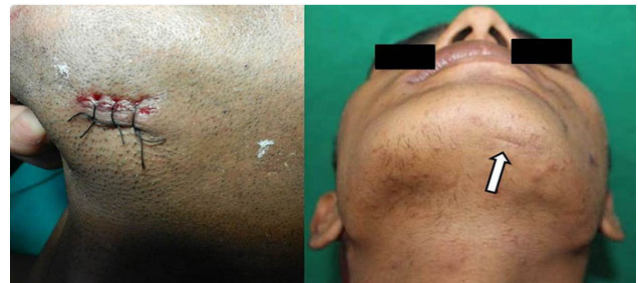[Table/Fig-6]: Diagrammatic Illustration (a) and clinical photograph (b) of the exteriorized endotracheal tube fixated with skin suture (b1) and further stabilized with adhesive tape (b2). The submental tube is reconnected to the breathing circuit



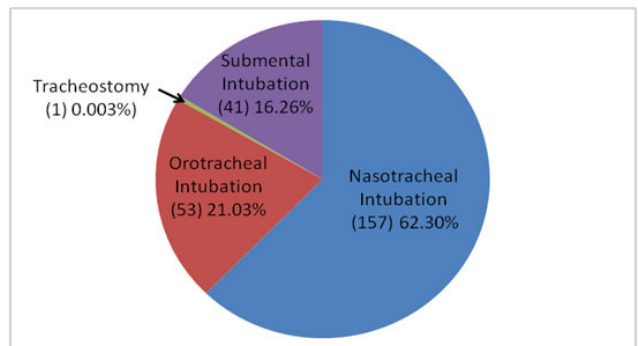
[Table/Fig-7]: Diagrammatic Illustration (a) and clinical photograph (b) showing the final position of the endotracheal tube in the paralingual groove

position of the anaesthetic tube was further confirmed by using the laryngoscope and by verifying whether the airway was patent. After establishing airway through SMI, the ET tube was fixed with 2-0 silk suture to the submental skin and stabilized with adhesive tape to prevent tube dislodgment [Table/Fig-6a,b]. The final position of the endotracheal tube was in the paralingual groove, which allowed complete freedom of lower jaw movement and establishment of occlusion [Table/Fig-7a,b].

After the surgery was completed stay sutures on submental skin was removed and both ET tube and pilot cuff were reversed intraorally. The cutaneous incision was closed by



[Table/Fig-8]: (a) Clinical photograph of closure of the incision with interrupted suture after the tube is reversed orally (Left) (b) the healing scar of submental incision (block arrow) at 4 month post-operatively (Right)



[Table/Fig-9]: Choice of route of intubation

two to three interrupted 4-0 prolene sutures [Table/Fig-8a]. The intraoral wound did not require closure. Extubation was then carried out as in classic OTI.

RESULTS

Out of 252 patients of facial bone fracture treated under general anaesthesia 41 (16.26%) were subjected to SMI [Table/Fig-9]. All the patients had combination of fracture involving dental occlusion (mandible & maxillary fractures) and fracture of fronto-naso-ethmoidal skeleton. Twelve cases had history of CSF rhinorrhoea subsequent to trauma involving mid and upper facial skeleton.

Length of incision for SMI varied from 1.5 to 2 cm. All the incisions were placed over skin in submental region slightly off the midline (paramedian), directly adjacent to the lower border of the mandible, except for midline incision used for the first case. Time required for the procedure (from placement of incision to establishment of submental airway) ranged from 8-20 minutes, with an average of 11.46 minutes. The entire process of shifting the ET tube (disconnection time from ventilator) was done swiftly and completed in less than two minutes (range of 1-1.5 min., with mean time of 1.23 min [n=41]). There was no significant desaturation of O₂ in any patient during the procedure of switching the ET tube from oral to submental region [Table/Fig-10]. All the patients were extubated at the end of the procedure after

Sr No.	Site and length of incision	Time of procedure (from placement of incision to establishment of SM airway)	Disconnection time from ventilator	Fall in oxygen saturation (during disconnection of breathing circuit)
1	Midline, 2cm	20 minutes	1.5 minutes	From 100 to 97%
2	Paramedian, 1.5cm	20 minutes	1 minute	From 100 to 98%
3	Paramedian, 1.5cm	14 minutes	1 minute	From 100 to 98%
4	Paramedian, 1.5cm	10minutes	1.5 minutes	No fall
5	Paramedian, 2cm	13 minutes	1.5 minutes	No fall
6	Paramedian, 1.5cm	12 minutes	1.5 minutes	No fall
7	Paramedian, 1.5cm	11 minutes	1.5 minutes	From 100 to 98%
8	Paramedian, 1.5cm	13 minutes	1 minute	No fall
9	Paramedian, 1.5cm	13 minutes	1 minute	No fall
10	Paramedian, 1.5cm	12 minutes	1 minute	No fall
11	Paramedian, 1.5cm	14 minutes	1.5 minute	No fall
12	Paramedian, 2cm	12 minutes	1.5 minutes	No fall
13	Paramedian, 2cm	13 minutes	1 minute	From 100 to 97%
14	Paramedian, 2cm	12minutes	1 minute	From 100 to 99%
15	Paramedian, 2cm	11 minutes	1.5 minutes	No fall
16	Paramedian, 1.5cm	10 minutes	1.5 minutes	No fall
17	Paramedian, 1.5cm	11 minutes	1 minute	From 100 to 99%
18	Paramedian, 2 cm	10 minutes	2 minutes	No fall
19	Paramedian, 1.5cm	10 minutes	1.5 minutes	No fall
20	Paramedian, 2cm	10 minutes	1.5 minutes	No fall
21	Paramedian, 2cm	13 minutes	1 minute	No fall
22	Paramedian, 1.5cm	12 minutes	2 minutes	No fall
23	Paramedian, 1.5cm	13 minutes	1.5 minutes	No fall
24	Paramedian, 1.5cm	10minutes	1 minute	No fall
25	Paramedian, 1.5cm	10 minutes	1 minute	No fall
26	Paramedian, 1.5cm	12 minutes	1 minute	From 100 to 98%
27	Paramedian, 1.5cm	11 minutes	1 minute	No fall
28	Paramedian, 1.5cm	10 minutes	1 minute	From 100 to 97%
29	Paramedian, 1.5cm	10 minutes	1 minute	From 100 to 98%
30	Paramedian, 1.5cm	13 minutes	1 minute	No fall
31	Paramedian, 1.5cm	10 minutes	1 minute	No fall
32	Paramedian, 2cm	9 minutes	1 minute	No fall
33	Paramedian, 1.5cm	10 minutes	1 minute	No fall
34	Paramedian, 1.5cm	10minutes	2 minutes	No fall
35	Paramedian, 2cm	9 minutes	1 minute	No fall
36	Paramedian, 1.5cm	10 minutes	1 minute	No fall
37	Paramedian, 1.5cm	10 minutes	1 minutes	No fall
38	Paramedian, 1.5cm	8 minutes	1.5 minutes	No fall
39	Paramedian, 1.5cm	10 minutes	1 minute	No fall
40	Paramedian, 1.5cm	10 minutes	1 minute	From 100 to 99%
41	Paramedian, 1.5cm	9 minutes	1 minute	No fall

[Table/Fig-10]: Intraoperative variables

reversing the ET tube from the submental to the oral route. No significant complication was associated with SMI, except for transient lingual haematoma over anterior floor of mouth in the first case, which resolved spontaneously within a week. The extraoral scar in all the patients healed with acceptable aesthetic result.

DISCUSSION

Choice of route of intubation in maxillofacial trauma

Oral and nasal routes of intubation are contraindicated in patient of jaw fracture associated with nasal complex fracture (due to interference with operative sites), persistent CSF leakage (due to risk of meningitis), obstruction of nasal airway by deviated nasal septum, hypertrophic turbinates or nasal polyp (due to lack of patent nasal passage) and anterior skull base fracture (due to risk of passage of ET tube into cranial cavity and brain damage) [6-9]. Options of airway management in such situations include, shifting the tube from oral to nasal or vice-versa during the surgery, doing surgery in two stages, Reteromolar Intubation (RMI) and tracheostomy. Intraoperative changing of tube position has its associated disadvantages and doing surgery in stages increases the associated risk as well as cost [10]. Tracheostomy has high rate of complication including tracheal stenosis, internal emphysema, laryngeal nerve damage, tracheoesophageal fistula, haemorrhage, pneumothorax, blockage or obstruction of cannula, major scarring and prolonged hospitalisation [10,11]. Despite its associated drawbacks tracheostomy is unavoidable in severe case of pan-facial trauma with unstable airway, which require protracted period of assisted ventilation [12,13]. RMI can be used in selected cases where the oral ET tube can be exteriorised by passing it from behind the posterior most teeth in the mouth without interfering with occlusion [14,15]. In our study submental route was used for airway management in patients with fracture of mandible and maxillary associated with nasal complex fracture and /or CSF rhinorrhoea.

Technique of SMI and modifications

Submental intubation was first reported by Francisco Hernandez Altemir in 1986 [16]. The original technique involves a 2 cm incision in the submental region. The subsequent dissection is extended cephalad, keeping it close to lingual surface of mandible, in the subperiosteal plane [17].

Altemir technique uses a single ET tube with detachable connector, which is exteriorized through the submental dissection plane. An alternative method of SMI was reported by Green and Moore, in 1996 when ET tube with detachable connector is not available [18]. In this technique the routine oral tracheal intubation is done and submental tunnel is created. A second ET tube is pulled from outside into the oral cavity through the submental tunnel. The original tube is

withdrawn and the second ET substituted. Altemir sequence is more popular and is associated with lesser complication than Green and Moore sequence [19].

Fibre or metal reinforced ET tube is preferred for SMI, due to the ability to maintain lumen patency at the acute tube angles as the tube passes from floor of the mouth onto the submental-submandibular region [20]. Other devices used for SMI includes non-reinforced ET tubes and laryngeal mask airways [21,22]. All our cases were done by Altemir technique, using a single reinforced endotracheal tube with detachable connector. The paramedian skin incision of 1.5- 2.0 cm length was used (kept about 1.5- 2.0 cm from the midline, directly adjacent to the lower border of the mandible).

The procedure of SMI is relatively simple and easy to learn. Time required for the procedure ranged from 8-20 minutes, with average of 11.6 minutes. In our initial cases the time required was more. But as the operator and the anaesthetic team got familiar with the procedure from the first few cases the working time was reduced considerably. In literature the reported time to carry out the procedure varies from 4 minutes [23] to 30 minutes [24], as compared to 41.7 minutes [25] required for tracheostomy.

Possible complications and limitations

Reported complication of SMI includes superficial skin infection [26], venous bleeding [27], oro-cutaneous fistula [17], keloid [28], damage, dislodgement and obstruction to ET tube, [29], mucocele formation, transient lingual nerve paresthesia [30], partial extubation [31], pilot balloon entrapment and detachment [31-35].

No significant complication was seen in our patients, except for lingual haematoma over anterior floor of mouth in the first case. The patient was kept on oral antibiotics post-operatively. The haematoma was transient and resolved spontaneously in a week. The anterior sublingual haematoma was possibly due to midline dissection through the genial muscles. We modified our subsequent cases with a paramedian incision placed in submental-submandibular region about 2 cm lateral to the midline. This avoided both the genial muscles & opening of submandibular duct in the midline and submandibular gland and lingual nerve posteriorly. The post-operative healing in all our cases was uneventful. The extraoral scar healed with acceptable anaesthetic result. Unlike tracheostomy which often leads to significant scarring, the incision mark of SMI was small and hidden well in the skin crease. However SMI should be used with caution in patient with history of hypertrophic scarring and keloid tendency.

CONCLUSION

According to our experience and reported cases in literature, SMI is extremely useful technique with very low rate of

complication. It offers faster, safer and economical alternative to tracheostomy for airway management in patients with maxillofacial injury where both oral and nasal intubations are contraindicated, and long term ventilation support is not required.

ACKNOWLEDGMENT

I would sincerely like to thank Dr. Dhulkhed and staff in department of anaesthesiology, KIMSDU, Karad for their valuable support and providing anaesthesia for our patients.

REFERENCES

- [1] Pavlakovic L, Lee G. Anaesthesia for maxillofacial Surgery. *Anaesthesia and intensive care medicine*. 12:8;360-64
- [2] Arora S, Rattan V, Bhardwaj N. An evaluation of the retromolar space for oral tracheal tube placement for maxillofacial surgery in children. *Anesth Analg*. 2006;103(5):1122-25.
- [3] Caron G, Paquin R, Martin RL, Claude AT, Pierre-Eric L. Submental Endotracheal Intubation: An Alternative to Tracheostomy in Patients with Midfacial and Panfacial Fractures. *The Journal of Trauma and Acute Care Surgery*. 2000; 48(2):235-40.
- [4] Taicher S, Givol N, Peleg M, Ardekian L. Changing indications for tracheostomy in maxillofacial trauma. *J Oral Maxillofac Surg*. 1996Mar;54(3):292-95.
- [5] Hernandez AE. The submental route for endotracheal intubation. *J Maxillofac Surg*, 1986; 14:64.
- [6] Schütz P, Hamed H. Submental Intubation Versus Tracheostomy in Maxillofacial Trauma Patients. *J Oral Maxillofac Surg*. 2008;66:1404-09.
- [7] Hall CEJ, Shutt LE: Nasotracheal intubation for head and neck surgery. *Anaesthesia*. 2003;58:249.
- [8] Marlow TJ, Goltra DD, Schabel SI. Intracranial placement of a nasotracheal tube after facial fracture: A rare complication. *J Emerg Med*. 1997; 15:187.
- [9] Muzzi DA, Losasso TJ, Cucchiara RF. Complication from a nasopharyngeal airway in a patient with basilar skull fracture. *Anesthesiology*. 1991; 74:366.
- [10] Bernard AC, Kenady DE: Conventional surgical tracheostomy as the preferred method of airway management. *J Oral Maxillofac Surg*. 1999; 57:310.
- [11] Waldron J, Padgham ND, Hurley SE. Complications of emergency and elective tracheostomy: A retrospective study of 150 consecutive cases. *Ann R Coll Surg Engl*. 1990;72:218.
- [12] Lewis RJ, Tracheostomies. Indications, timing, and complications. *Clin Chest Med* 1992;13:137-49.
- [13] Zeitouni AAG, Kost KM. Tracheostomy: a retrospective review of 281 cases. *J Otolaryngol*. 1994;23:61-66.
- [14] Taicher R, Navot G, Peleg M, et al. Changing indications for tracheostomy in maxillofacial trauma. *J Oral Maxillofac Surg*. 1996;54:292,
- [15] Martinez LJJ, Eslava JM, Cebrecos AI, Marcos O. Retromolar intubation. *Journal of Oral and Maxillofacial Surgery*. 1998; 56: 302-05.
- [16] Altemir FH. The submental route for endotracheal intubation. A new technique. *J Maxillofac Surg*. 1986;14:64-65.
- [17] Tagliatalata S C, Maio G, Aliberti F, Tagliatalata S, Grimaldi PL. Submento-submandibular intubation: is the subperiosteal passage essential? Experience in 107 consecutive cases. *Br J Oral Maxillofac Surg*. 2006 Feb;44(1):12-14.
- [18] Green JD, Moore UJ. A modification of submental intubation. *Br J Anaesth* 1996;77: 789-91.
- [19] Jundt JS, Cattano D, Hagberg CA, Wilson JW. Submental intubation: a literature review. *Int. J. Oral Maxillofac. Surg*. 2012;41(8):1030.
- [20] Meyer C, Valfrey J, Kjartansdottir T, Wilk A, Barrière P. Indication for and technical refinements of submental intubation in oral and maxillofacial surgery. *J Craniomaxillofac Surg*. 2003;31:383-88.
- [21] Altemir FH, Montero SH. The submental route revisited using the laryngeal mask airway: a technical note. *J Craniomaxillofac Surg*. 2000;28(6):343-44.
- [22] Rahpeyma A, Ahmadi SK. Submental Intubation in Maxillofacial Trauma Patient. *S. Iran J Otorhinolaryngol*. 2013; 25(70): 17-22.
- [23] Nyárády Z, Sa'ri F, Olasz L, Nyárády J. Modified submental endotracheal intubation in concurrent orthognathic surgery. *Mund Kiefer Gesichtschir* 2004;8:387-89.
- [24] Choi S, Song SH, Kang NH. Modified submental intubation in panfacial bone fracture patients. *J Korean Soc Plast Reconstr Surg* 2011;38:127-29.
- [25] Freeman BD, Isabella K, Perren CJ, Boyle WA, Schmiege RE, Koloff MH, et al. A prospective, randomized study comparing percutaneous with surgical tracheostomy in critically ill patients. *Crit Care Med* 2001;29:926-30.
- [26] Garg M, Rastogi B. Submental intubation in panfacial injuries: our experience. *Dental Traumatol*. 2010; 26: 90-93.
- [27] Agrawal M, Kang L. Midline sub-mental orotracheal intubation in maxillofacial injuries: a substitute to tracheostomy where postoperative mechanical ventilation is not required. *J Anesthesiol Clin Pharmacol* 2011;26:498-502.
- [28] Gadre KS, Waknis PP. Transmylohyoid/Submental intubation: review, analysis, and refinements. *J Craniofac Surg*. 2010;21(2):516-9.
- [29] Navaneetham A, Thangaswamy VS, Rao N. Submental intubation: our experience. *J Maxillofac Oral Surg*. 2010;9:64-67.
- [30] Chandu A, Witherow H, Stewart A. Submental intubation in orthognathic surgery: initial experience. *Br J Oral Maxillofac Surg*. 2008 Oct;46(7):561-63.
- [31] Sharma Rk, Tuli P, Cyriac C. Submental tracheal intubation in oromaxillofacial surgery. *Indian J Plast Surg* 2008; 41: 15-19.
- [32] Langford R. Complication of submental intubation. *Anaesth Intensive Care*. 2009;37(2):325-26.
- [33] Yoon KB, Choi BH, Chang HS, Lim HK. Management of detachment of pilot balloon during intraoral repositioning of the submental endotracheal tube. *Yonsei Med J*. 2004;45(4):748-50.
- [34] Antonio FC, Belmiro CV, Ricardo JHV, Henrique A M, Nelson S R. Submental intubation in Oral Maxillofacial Surgery. Review of the literature and analysis of 13 cases. *Med Oral Patol Oral Cir Bucal*. 2008 Mar;13(3):E197-200.
- [35] MacInnis E, Baig M. A modified submental approach for oral endotracheal intubation. *Int J Oral Maxillofac Surg*. 1999;28:344-46.

AUTHOR(S):

1. Dr. Kumar Nilesh
2. Dr. Neelima A Malik
3. Dr. Pankaj Patil
4. Dr. Nilesh Patil
5. Dr. Shambhvi Malik
6. Dr. Mayuri Jobanputra

PARTICULARS OF CONTRIBUTORS:

1. Reader, Department of Oral & Maxillofacial Surgery School of Dental Sciences, KIMSDU, Karad, India.
2. Professor & HOD, Department of Oral & Maxillofacial Surgery School of Dental Sciences, KIMSDU, Karad
3. Lecturer, Department of Oral & Maxillofacial Surgery School of Dental Sciences, KIMSDU, Karad, India.
4. Reader, Department of Oral & Maxillofacial Surgery School of Dental Sciences, KIMSDU, Karad, India.

5. Lecturer, Department of Prosthodontics, School of Dental Sciences, KIMSDU, Karad, India.
6. Post-Graduate Student, Department of Oral & Maxillofacial Surgery, School of Dental Sciences, KIMSDU, Karad, India.

NAME, ADDRESS, E-MAIL ID OF THE CORRESPONDING AUTHOR:

Dr. Kumar Nilesh

Reader, Department of Oral & Maxillofacial Surgery, School of Dental Sciences, Krishna Hospital, Karad, Satara, Maharashtra-415 110, India.

E-mail: drkumarnilesh@yahoo.com

FINANCIAL OR OTHER COMPETING INTERESTS:

None.

Date of Publishing: Jul 01, 2015