

Multiple Amoebic Liver Abscesses: A Case Report

HARISH KUMAR, VEER BAHADUR SINGH, JATIN AGRAWAL, RAJESH KUMAR

ABSTRACT

Amoebic liver abscess is common in tropical country, caused by a protozoan *Entamoeba histolytica*. It is the most common extra intestinal manifestation caused by invasion of amoeba. It is presented as fever, right hypochondria pain with tenderness and hepatomegaly. In recent year mortality by liver abscess is decreases by early diagnosis with ultrasonography. Most amoebic liver abscess presented with

single and large. Multiple liver abscesses are not uncommon but in number of 15 liver abscesses are rare. Here we are presenting a case of 15 liver abscesses who was symptomatic in spite of intra venous antibiotics with metronidazole and ciprofloxacin of 7 days treatment. Symptoms were improved after ultrasonography guided percutaneous aspiration of large abscess. So aspiration has an important role in multiple liver abscesses.

Keywords: Amoeba, Aspiration, Metronidazole, Ultrasonography

CASE REPORT

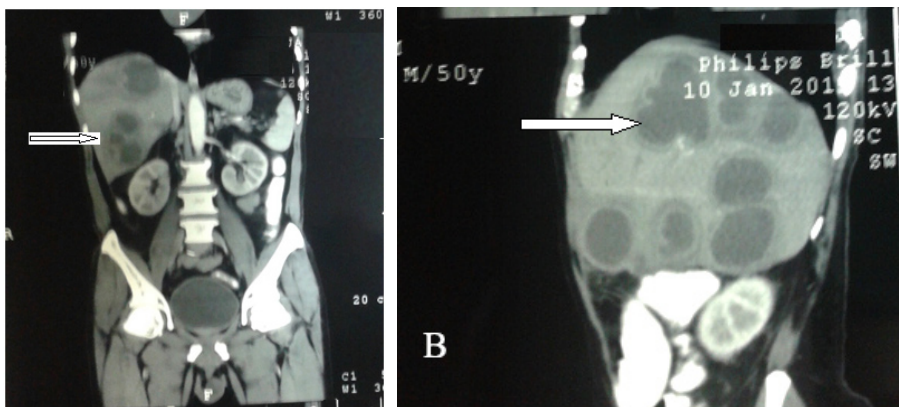
A 50 years old alcoholic male was admitted in department of medicine with a 10 days history of high grade fever, right upper quadrant pain. Patient has already taken for treatment of liver abscess from outside diagnosed by ultrasonography. He was treated for 7 days with intravenous metronidazole and ciprofloxacin from outside for liver abscess. Despite treatment he was presented with high grade fever, right upper quadrant pain. Patient had no history of diarrhea and breathlessness.

On examination patient was conscious cooperative and well oriented. His auxiliary temperature was 102°F. He has mark tenderness over the right hypochondria with enlarged liver (5 cm below the costal margins). His pulse was 100 per minute, respiration 20 per minute regular abdominothoracic, blood pressure 110/90 mmHg. Patient was neither dyspnoeic nor have any skin rash and lymphadenopathy. Laboratory test revealed white blood cells 19000/mm³ with polymorphs 85%, lymphocytes 10% and monocytes 12%. Hemoglobin was 9.8 g/dL with mild microcytic hypochromic. Ultrasonography revealed multiple hypo echoic area in both the lobe largest approximately 63x64 mm with thick wall bowel loop in right iliac fosse suggestive of amoebic typhlitis. Serum was positive for *E. histolytica* IgG antibody on day 7 with 2.226 units. The test detects IgG antibody specific for *E. histolytica*. Gall bladder and bile duct was normal in both ultrasound and computed tomography scan. Chest X-ray and other investigation were normal. Stool microscopy was normal.

Patient was early diagnosed as multiple liver abscess 7 days back from outside before admission for which he has already taken intra venous metronidazole and ciprofloxacin but could not improved. After admission patient was started on intravenous ceftriaxone and metronidazole. Fever and abdominal pain was continuous for two days. So we have investigated further with contrast enhanced CT scan of abdomen. Computed tomography of abdomen showed multiple liver abscesses with the number of 15, largest one measuring approximately 51x57x55 mm in right lobe of liver with impending to rupture [Table/Fig-1a,1b]. Ultrasound guided percutaneous needle aspiration of largest abscess was done. 200 ml brownish color fluid was aspirated from largest one and 50 ml from other small abscesses. Microscopy of smear shows polymorphs only, with no other organism, trophozoites and acid fast bacilli seen. Anaerobic culture was negative. After the 4 day of aspiration patient shows marked improvement. By day 5, patient's temperature was normal and abdominal pain and tenderness subside. Appetite becomes normal by 10th day. He was discharged and keep on oral with metronidazole and ciprofloxacin for next 15 days.

DISCUSSION

In the developing countries, intestinal amoebiasis is far more common than developed country, due to poor sanitation. Worldwide approximately 40 million suffer by it with case fatality rate of approximately 1/1000. Case fatality has decreased



[Table/Fig-1a,b]: CECT abdomen showing multiple liver abscesses

now by use of noninvasive technique of ultrasonography for both of diagnostic as well as therapeutic for aspiration of liver abscess as mentioned by Guglielmi et al., and Kapoor et al., [1,2]. Here we are discussing a case of multiple large liver abscesses presented with fever, right upper quadrant pain with tenderness and hepatomegaly that was only improved after percutaneous aspiration of multiple large abscesses. Single liver abscess are far more common with approximately seventy present but multiple was not exceptional. Our case present with multiple amoebic liver abscesses without superimposed bacterial infection who was not improved by 7 days treatment of intravenous metronidazole and ciprofloxacin inspite of early diagnosis by ultrasonography. Thus aspiration of abscesses has the importance in multiple liver abscesses. Amoebic liver abscess is more common in developing country and, worldwide amoebas are the commonest cause [3]. The prevalence of pyogenic abscess is more in developed country.

Infection of amoebic liver abscess is spread by contaminated food, water by amebic cysts. It can also transmitted by faeco-oral route. Classical clinical presentation of liver abscess is fever, right upper quadrant pain and liver tenderness. Clinical examination revealed hepatomegaly and jaundice and anemia. USG is the imaging of first choice. It is quick, safe, cheap, and accurate in picking a liver lesion. A complication of liver abscess is reduced due to early diagnosis by ultrasound, which is the gold standard test of liver abscess [4,5]. Complication of liver abscess is due to rupture of it, into peritoneal cavity cause peritonitis, into pericardial cavity leads to cardiac tamponade and may perforate by extension in to abdominal wall [6]. Reactive pleural effusion is the most common complication of liver abscess. Serological test of *E. histolytica* is more sensitive and specific than microscopy with IgG antibody have 95% of sensitivity and 91% specificity according to Sathar et al.,[7]. In extra intestinal amoebiasis antibody detection is about 95%, 70% of active intestinal infection, and in 10% of asymptomatic person. Invasive intestinal and extra intestinal

amoebiasis accounts for about 10% of the cases. The sensitivity by EIA is about 64% in patients with current invasive disease and shown to be better than indirect hemagglutination (IHA). Demonstrable systemic humoral immune response is seen in about one week after the onset of symptoms. Antibody detection is more useful when organism is not found in stool examination in amoebic liver abscess. Anti-amoebic antibodies may persist even after invasive amoebiasis has healed or after subclinical infection.

Metronidazole is the treatment of choice in amoebic liver abscess with cure rate of more than 90 percent [8]. Prolonged course may be needed in case of slow response by metronidazole. Resistant to metronidazole has not been reported [9]. In our case in spite of giving of 7 days of intravenous metronidazole in full dose patient was not improved which may be due to a large number of liver abscesses. In present case abscess was not super imposed by bacterial infection. Thus for early improvement aspiration is the better choice than prolonged course of intravenous antibiotics. Therapeutic percutaneous aspiration is rarely need in amebic liver abscess [10,11]. Even large size and multiple abscesses are better treated by antibiotics. Most amoebic liver abscess respond to medical treatment but there are some studies define clearly the role of aspiration in the treatment of Amoebic liver abscess [12,13]. Aspiration is mainly indicated in impending to rupture in adjacent cavities and patients who are not improving after 48-72 hr in spite of giving antibiotics. Pain and tenderness also improved by aspiration by relieve decompression of the liver capsule. Aspiration of acellular debris also reduce the inflammatory reaction subside the fever more rapidly. Thus, aspiration of large abscess is necessary for early diagnosis and decrease complication in severe disease. Amoeba usually not demonstrated in aspirate and in microscopy because its adherent to the wall of abscess cavity. In the present case despite of early diagnosis and early treatment, aspiration needed, therefore, percutaneous aspiration by ultrasound guided can reduced the mortality.

CONCLUSION

About 90% of the cases of *E. histolytica* are asymptomatic. Our patient presented with 15 multiple liver abscesses, despite of treatment he was not improved. Improvement occurred by percutaneous aspiration. So in multiple liver abscesses therapeutic percutaneous aspiration and antibiotics has better role than only antibiotics.

REFERENCES

- [1] Guglielmi A, Veraldi GF, Furlan F, Brunelli G, De Manzoni G, Negri A, et al. The conservative treatment of hepatic abscesses with echo-guided transcutaneous drainage. *Ann Ital Chir.* 1991;62(1):7-12.
- [2] Kapoor R, Saha MM, Talwar S. Ultrasonic evaluation of intra-abdominal abscesses. *Indian Pediatr.* 1991;28(7):757-60.
- [3] Krige JEJ. Pyogenic liver abscess. In: Kirsch R, Robson S, Trey C, eds. *Diagnosis and management of liver disease.* London: *Chapman and Hall.* 1995; 196-202.
- [4] Schwerk WB, Maroske D, Roth S, Arnold R. Ultrasound-guided fine-needle puncture in the diagnosis and therapy of liver and spleen abscesses. *Dtsch Med Wochenschr.* 1986; 111(22):847-53.
- [5] Ralls PW, Barnes PF, Radin DR, Colletti P, Halls J. Sonographic features of amoebic and pyogenic liver abscesses: a blinded comparison. *Am J Roentgenol.* 1987;149(3):499-501.
- [6] Adams EB, MacLeod IN. Invasive amoebiasis. II. Amoebic liver abscess and its complication. *Medicine(Baltimore).* 1977;56(4):325-34
- [7] Sathar M.A., Simjee A.E., Nel J.D., Bredenkamp B.L., Gathiram, V. and Jackson T.F. Evaluation of an enzyme-linked immunosorbent assay in the serodiagnosis of amoebic liver abscess. *South African Medical Journal.* 1988; 74(12), 625-28.
- [8] Li E, Stanley SL. Protozoa. Amoebiasis. *Gastroenterol Clin North Am.* 1996;25(3):471-92.
- [9] Ravdin JL, Skilogiannis J. In vitro susceptibilities of *Entamoeba histolytica* to azithromycin, CP -63956, erythromycin and metronidazole. *Antimicro Agent Chemother.* 1989;33:960-62.
- [10] Blessmann J, Binh HD, Hung DM, Tannich E, Burchard G. Treatment of amoebic liver abscess with metronidazole alone or in combination with ultrasound guided needle aspiration: a comparative, prospective and randomized study. *Trop Med Int Health.* 2003;8(11):1030-34.
- [11] Sharma MP, Rai RR, Acharya SK, Ray JC, Tandon BN. Needle aspiration of amoebic liver abscess. *Br Med J.* 1989;299(6711):1308-09.
- [12] De La Rey Nel J, Simjee AE, Patel A: Indications for aspiration of amoebic liver abscess. *S Med J.* 1989; 75(8):373-76.
- [13] Porras-Ramir G, Hernandez-Herrera MH, Porras-Hernandez JD: Amoebic hepatic abscess in children. *J Pediatr Surg.* 1995; 30:660-64.

AUTHOR(S):

1. Dr. Harish Kumar
2. Dr. Veer Bahadur Singh
3. Dr. Jatin Agrawal
4. Dr. Rajesh Kumar

PARTICULARS OF CONTRIBUTORS:

1. Senior Resident, Department of Medicine, S P Medical College, Bikaner (Rajasthan), India.
2. Senior Professor, Department of Medicine, S P Medical College, Bikaner (Rajasthan), India.
3. Registrar, Department of Medicine, S P Medical College, Bikaner (Rajasthan), India.

4. Registrar, Department of Medicine, S P Medical College, Bikaner (Rajasthan), India.

NAME, ADDRESS, E-MAIL ID OF THE CORRESPONDING AUTHOR:

Dr. Harish Kumar,
Department of Medicine, PBM Hospital, Bikaner,
Rajasthan -334001, India.
E-mail: drharishsgnr@gmail.com

FINANCIAL OR OTHER COMPETING INTERESTS:

None.

Date of Publishing: Oct 01, 2015