

Anatomical Study of Parietal Emissary Foramina in Human Skulls

SHANTHARAM V, KY MANJUNATH

ABSTRACT

Introduction: Emissary veins connect the intracranial venous sinuses with the veins outside the cranium. The foramina of the skull through which they traverse are known as emissary foramina. The emissary veins are valve less, so, blood can flow bidirectionally and serve an important function of equalizing intracranial pressure and can act as safety valves during cerebral congestion.

Aim: To find out the frequency of occurrence of the parietal emissary foramina in adult South Indian skulls and their topographical location with reference to the sagittal suture and the lambda.

Materials and Methods: A collection of 78 adult skulls of unknown sex were examined for the occurrence of parietal emissary foramina. The size of the foramina was measured

with a digital caliper. Distances between the foramen and the sagittal suture and the lambda were also measured with a digital caliper.

Results: The parietal emissary foramina were absent in 69 (44.231%) sides out of 156 sides of the skulls examined. They were found in 87 (55.77%) sides out of 156 sides of the skulls examined. The parietal foramina were found to be located at a distance ranging from 2 mm-36 mm from the sagittal suture. From the lambda they were found to be located at a distance of 7 mm-56.1 mm. The diameter of the parietal foramina was in the range of 0.86 mm-5.57 mm.

Conclusion: Localisation of parietal foramina is important for the neurosurgeon to prevent accidental haemorrhage resulting from damage to the parietal emissary veins.

Keywords: Cranial foramina, Cranium, Diploic veins, Dural venous sinuses, Scalp veins

INTRODUCTION

Emissary veins connect the intracranial venous sinuses with the veins outside the cranium. The foramina of the skull through which they traverse are known as emissary foramina [1]. The emissary veins are valve less, so, blood can flow bidirectionally and serve an important function of equalizing intracranial pressure and can act as safety valves during cerebral congestion. Emissary veins are also considered as important for brain cooling [2]. The frequency of occurrence of the emissary foramina varies individual to individual and not all of the emissary foramina can be found in every individual [3-5]. The parietal emissary veins connect the scalp veins with the superior sagittal sinus, foramina transmitting these veins are usually found bilaterally on either side of sagittal suture approximately at the junction of posterior and middle third of parietal bone [1,5,6]. There are only a few Indian studies about the parietal emissary foramina [6,7]. One such study carried out by Rajpurohit GK and Babu Y [7] on south Indian skulls was based on a very small sample of 20 skulls.

The present study is focussed on the occurrence of the

parietal emissary foramina in adult South Indian population and their topographical location with reference to the sagittal suture and the lambda.

MATERIALS AND METHODS

The present report is an observational study carried out to ascertain the frequency of occurrence of the parietal emissary foramina, their size and location on the vault of the cranium. The study was carried out during the year 2016. using a collection of 78 adult skulls of unknown sex available at Akash Institute of Medical Sciences and Research Centre, Bengaluru, India, Only adult skulls, not showing any damage or deformities in the region of skull vault were included in the study. Those skulls showing changes due to breakage, pathological lesions or neurosurgical procedures were excluded from the study. The authors recorded observations independently and the data was compared before processing.

The variations of occurrences of the parietal foramen were scored as absent, unilateral, bilateral, and single or double. The size of the foramina was measured with a digital caliper to the nearest millimetre.

The parietal foramina are located lateral to the sagittal suture, at the junction of the posterior and middle third of the parietal bone anterior to the lambda. Distance between the foramen and the sagittal suture and the lambda were also measured with a digital caliper to the nearest millimetres, mean and standard deviation was calculated.

RESULTS

One hundred and fifty six parietal bones of seventy eight skulls were examined for the present study.

The parietal emissary foramina were absent in 69 (44.231%) out of 156 parietal bones examined. They were found in 87 (55.77%) out of 156 parietal bones examined [Table/Fig-1]. In 74 skulls a single foramen was found. Double foramina were found in four skulls; bilaterally in one skull and unilaterally in three skulls (in two on right side and in one on left side) [Table/Fig-2-4]. A student 't'-test did not show any statistically significant difference ($p < 0.05$) between parietal foramina.

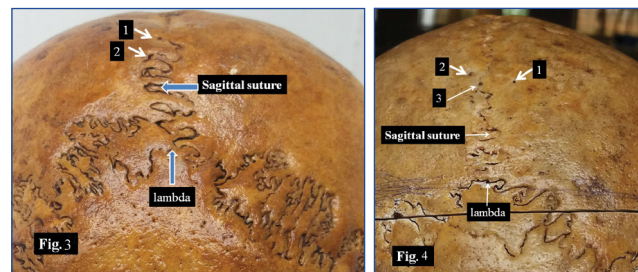
Topographical location and size: The parietal foramina were found to be located at varying distance lateral to the

n=78	Bilateral	Unilateral		Total no of sides
		Right	Left	
No. of skulls absent	21 (26.92%)	12	15	69/156 (44.231%)
No. of skulls present	29 (37.18%)	16	13	87/156 (55.77%)
Distance from sagittal suture (Mean±SD)	Right (mms)	Right (mm)	Total (mm)	
	07.41±4.86	07.26±3.18	07.34±4.12	
Distance from lambda (Mean±SD)	38.06±10.5	37.82±6.31	37.95±8.75	
Diameter (Mean±SD)	01.91±0.70	02.08 ±0.85	01.99±0.78	

[Table/Fig-1]: Frequency of occurrence, size and topographical location of parietal emissary foramina in the present study.



[Table/Fig-2]: Shows two parietal foramina (1,2) of unequal size located one behind the other on the right side.



[Table/Fig-3]: Shows two parietal foramina (1,2) of almost equal size one located on the left side of the sagittal suture and the other along the sagittal suture. **[Table/Fig-4]:** Shows three parietal foramina (1,2,3); two located bilaterally on either side of the sagittal suture and one on the. Sagittal suture itself.

Author, Year/ Population group	Material Examined and Sample size	Unilateral	Bilateral	Absent
Boyd GI, 1930/ British [3]	1500 skulls	40.5	19.9	39.6
Yoshioka N et al., 2006/USA [10]	20 adult cadavers	20	40	40
Murlimanju BV et al., 2015/Coastal South Indians [6]	58 skulls and 116 parietal bones	32.7	55.2	12.1
Rajpurohit GK et al., 2017/South Indians [7]	20 skulls	25	40	20
Present study/ South Indians	78 skulls	18.59	37.18	44.23

[Table/Fig-5]: Comparison of frequency of occurrence of parietal emissary foramen with previous studies.

sagittal suture, at the boundary between the posterior third and middle third of parietal bone. In one case it was located directly on the sagittal suture itself. The parietal foramina were found to be located at a distance ranging from 2 mm-36 mm from the sagittal suture. From the lambda they were found to be located at a distance of 7.0-56.1 mm. The diameter of the parietal foramina was in the range of 0.86-5.57 mm [Table/Fig-1-4]. To find out the statistically difference between the parietal bones of two sides the data on diameter of the parietal foramina and their distance from sagittal suture and lambda, were statistically analysed using student 't'-test. No statistically significant differences ($p < .05$) was found between the parietal bones of two side.

DISCUSSION

The parietal emissary veins connect the superior sagittal sinus with the occipital vein and also with the diploic veins within the cranial bones [1,2,5]. Both the parietal and mastoid emissary veins are found at high frequencies in Homosapiens compared with other hominid species [2-4]. The parietal foramina are located on either side of the sagittal suture. Their location usually coincides with junction between the middle 1/3rd and posterior 1/3rd of the parietal bone. The feature formed by the

parietal foramina when present bilaterally on either side of the sagittal suture has been named as the obelion, because of its similarity to the Greek symbol 'obelos' (÷) [6,8,9].

Frequency of occurrence: According to the studies carried out among the various population groups all over the world on parietal foramina reported in literature the frequency of its occurrence varies from 50%-80% [5,10,11]. Among specimens examined by Murlimanju BV et al., [6] the prevalence of foramen was higher in comparison to the data of Yoshioka N et al., [10] and Boyd GI [3] studies [Table/Fig-5]. Perhaps this is because of the racial variations. In spite of the specimens examined in our study, was racially similar to the study of Murlimanju BV et al., [6] the incidence was found to be lesser than their study. Perhaps this is indicative of ethnic variation. Boyd GI reported that the unilateral parietal foramen is seen more common on the right side than the left (20.7%:15.2%) [3]. According to Yoshioka N et al., the difference in occurrence of the parietal foramen is due to difference in ossification process of the anterior fontanelle [10]. In some cases, a small transverse parietal suture may be found in one or both sides at this region.

Size and shape: Wysocki J et al., found an average size of the parietal foramen to be twice in female skulls in comparison to the males in Polish population, thus suggesting a sexual dimorphism in the parietal ossification [11]. Boyd GI has reported that the average size of this foramen is less than 0.5 mm and a size larger than 1.5 mm is rare [3]. The diameter of the parietal foramina in the present study was in the range of 0.86 mm-5.57 mm [Table/Fig-1]. Boyd GI reported that the parietal foramina are larger in Australian and New Zealand people than the other races [3]. In the present study the parietal emissary foramen was not of larger size. The study by Murlimanju BV et al., has not quoted the size of the parietal foramina [6]. The parietal foramen has been reported to occur in various shapes-circular, oval or fissure [3,12-14]. However, in the present study all parietal foramina were found to be circular in shape.

Topographical location: In the study by Murlimanju BV et al., the distance of the foramen from the sagittal suture ranged from 0.5 mm to 13 mm and 1 mm to 15 mm on the right and left side respectively whereas, in the present study they were found to be located at a greater distance [Table/Fig-1]. However, their study did not mention the distance from the lambda [6]. According to Wysocki J et al., the position of the parietal foramen in newborns was found to be 2 cm anterior to the lambda. While in adults, this foramen was located 2-5 cm anterior to the external occipital protuberance [11].

Applied anatomy and clinical significance of the study: The emissary foramina are considered as typical character

in the human beings, they are less frequent in lower animals and in some species they are absent [3]. There exists an important relationship between the emissary foramina and the diploic veins of the skull, which are involved in the spread of infection from the extra cranial veins to intracranial sinuses. The topographical location of the parietal emissary foramen with reference to sagittal suture is clinically important to the neurosurgeon as the emissary veins may be ruptured during the surgical procedure and cause spontaneous bleeding. The parietal foramina usually have a well defined margin which is of help to the radiologist in differentiating from other pathological conditions like lytic lesions and the burr holes caused by the neurosurgical procedures. Many pathological conditions like cerebral venous and cortical anomalies, and skull fractures have been reported in association with enlarged parietal foramina [15-17]. Some authors are of the opinion that the data on skull foramina size and symmetry is important because such data may be of help to the radiologists in making difficult diagnoses of pathologic conditions of skull foramina using advanced radiologic techniques. A detailed knowledge of the morphologic variations in the foramina, of the skull vault is vital to performing safe radical surgery [18].

The importance of studying anatomy of emissary foramina has been emphasized by observation of Sir Frederick Treves who has remarked that "If there were no emissary veins, injuries and diseases of the scalp would lose half their seriousness" [2]. The present study has provided the data on the distance of the foramen from the sagittal suture as well as from lambda.

LIMITATION

Sexual predominance in the occurrence of parietal foramina could be determined in the present study since the skulls used were of unknown sex. Examination of larger sample of skulls of known sex may yield be of use in deciding sexual dimorphism. Due to non availability of studies from other parts of India ethnic variability could not be compared.

CONCLUSION

Over 55% of the parietal bones out of 156 parietal bones studied showed presence of parietal foramina. There was no statistically significant difference between the sides with reference to the occurrence of the parietal foramina. The frequency of occurrence however is less when compared to the only one Indian study available, The present study has provided the data on the size as well as topographical location of the parietal foramen with reference to the sagittal suture as well as the lambda. Localisation of parietal foramina is important for the neurosurgeon to prevent accidental haemorrhage resulting from damage to the parietal emissary veins.

REFERENCES

- [1] Standing S. Skull and Mandible. In: Gray's Anatomy: Anatomical Basis of Clinical Practice Standing S (Ed). 39th International Edition, Elsevier Churchill Livingstone, Edinburgh. 2005. pp 461.
- [2] Mortazavi MM, Tubbs RS, Riech SI, Verma K, Shoja MM, Zurada A, et al. Anatomy and pathology of the cranial emissary veins: a review with surgical implications. *Neurosurgery*. 2012;70:1312-19.
- [3] Boyd GI. The emissary foramina of the cranium in man and the anthropoids. *J Anat*. 1930;65:108-21.
- [4] Bergman RA, Afifi AK and Miyauchi R. Illustrated Encyclopedia of Human Anatomic Variation: opus V: skeletal systems: Cranium, 1995.
- [5] Freire AR, Rossi AC, De Oliveira VC, Prado FB, Caria PH, Botacin PR. Emissary foramina of the human skull: anatomical characteristics and its relations with clinical neurosurgery. *Int J Morphol*. 2013;31:287-92.
- [6] Murlimanju BV, Saralaya MS, Somesh VV, Prabhu LV, Krishnamurthy A, Chettiar GK, et al. Morphology and topography of the parietal emissary foramina in South Indians: an anatomical study. *Anat Cell Biol*. 2015;48:292-98.
- [7] Rajpurohit GK and Babu Y. Morphometric analysis of the emissary foramina of the skull. *Int J Recent Sci Res*. 2017;8(3):16227-29.
- [8] Freire AR, Rossi AC, De Oliveira VC, Prado FB, Caria PH, Botacin PR. Emissary foramina of the human skull: anatomical characteristics and its relations with clinical neurosurgery. *Int J Morphol*. 2013;31:287-92.
- [9] Mann RW, Manabe J, Byrd JE. Relationship of the parietal foramen and complexity of the human sagittal suture. *Int J Morphol*. 2009;27:553-64.
- [10] Yoshioka N, Rhoton AL Jr, Abe H. Scalp to meningeal arterial anastomosis in the parietal foramen. *Neurosurgery*. 2006; 58:58(1):123-26.
- [11] Wysocki J, Reymond J, Skarzyński H, Wróbel B. The size of selected human skull foramina in relation to skull capacity. *Folia Morphol (Warsz)*. 2006;65:301-08.
- [12] Mann RW. Enlarged parietal foramina and craniosynostosis in an American Indian child. *Am J Roentgenol*. 1990;154(3):658.
- [13] Keats TE. Atlas of normal roentgen variants that may simulate disease. 5th ed. St. Louis, MO: Mosby Year Book; 1992.
- [14] Griessenauer CJ, Veith P, Mortazavi MM, Stewart C, Grochowisky A, Loukas M, Tubbs RS. Enlarged parietal foramina: a review of genetics, prognosis, radiology, and treatment. *Childs Nerv Syst*. 2013;29:543-47.
- [15] Reddy AT, Hedlund GL, Percy AK. Enlarged parietal foramina: association with cerebral venous and cortical anomalies. *Neurology*. 2000;54(5):1175-78.
- [16] Edwards LS, Sachs JR, Elster AD. Skull fractures through parietal foramina: report of two cases. *J Comput Assist Tomogr*. 2012;36(3):308-09.
- [17] Agarwal P, Pandey M, Baranwal S, Roy K. Large midline persistent parietal foramina with occipital encephalocele and abnormal venous drainage. *J Cleft Lip Palate Craniofac Anomal*. 2015;2:66-69.
- [18] Berge JK and Bergman RA. Variations in size and in symmetry of foramina of the human skull. *Clin Anat*. 2001;14(6):406-13.

AUTHOR(S):

1. Dr. Shantharam V
2. Dr. KY Manjunath

PARTICULARS OF CONTRIBUTORS:

1. Assistant Professor, Department of Anatomy, Akash Institute of Medical Sciences and Research Centre, Bengaluru, Karnataka, India.
2. Professor, Department of Anatomy, Annapoorna Medical College, Salem, Tamil Nadu, India.

NAME, ADDRESS, E-MAIL ID OF THE CORRESPONDING AUTHOR:

Dr. Shantharam V,
Assistant Professor, Department of Anatomy, Akash
Institute of Medical Sciences and Research Centre,
Bengaluru-562110, Karnataka, India.
E-mail: shansdenovo@gmail.com

FINANCIAL OR OTHER COMPETING INTERESTS:

None.

Date of Publishing: Jan 01, 2018