

Transient Osteoporosis of Hip Presenting as Stress Fracture

RAHUL DEV

ABSTRACT

Transient Osteoporosis of Hip (TOH) is a rare idiopathic, reversible, rapidly developing and spontaneously resolving osteoporosis, a diagnosis of exclusion. It is seen more commonly in middle aged men, though also seen in the third trimester of pregnancy. The affected individuals present clinically with acute hip pain, limping gait and limited range of hip motion. We present a case report of a middle age female

patient of postpartum status presented with bilateral hip symptoms more prominent on the right side. Radiographs are typically unremarkable in this entity, but MRI is the main diagnostic tool which revealed imaging findings conforming bone marrow oedema and presence of stress fracture in the right femoral neck. TOH often resembles osteonecrosis, but the two conditions must be differentiated due to different prognosis and management approaches.

Keywords: Bone marrow, Hip, Osteoporosis, Transient

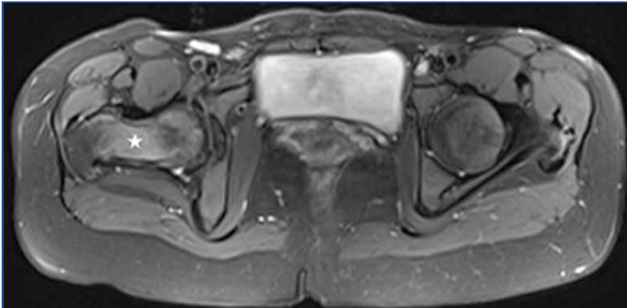
CASE REPORT

A 28-year-old female patient was referred to our department from orthopaedics outpatient clinic for MRI of hips. The patient complains of hip pain for past six months. Initially the pain was mild in nature, but increased progressively. More pronounced on the right side as compared to left, the patient was not able to put weight on her right lower limb. There was no significant pain during rest. The patient has the history of two spontaneous abortions in the last one year. The last child was born two years ago. No history of trauma, fever or other joint involvement was reported by the patient.

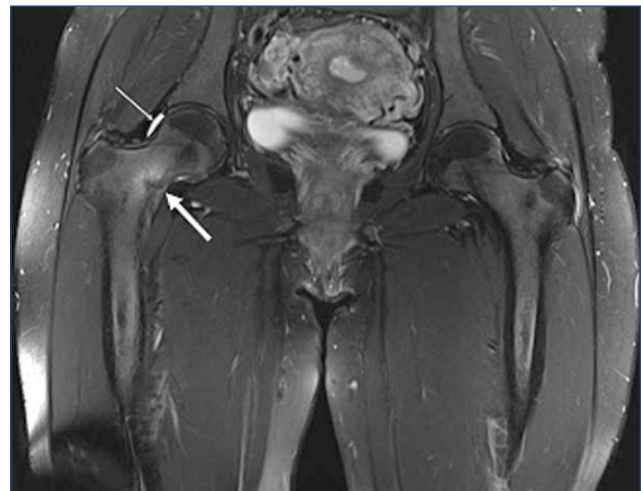
On examination, there was a limited range of movement involving both hips more evident on the right side, with a significant limp during walking on the right side. All the laboratory investigations were normal except mild elevation of ESR. In the view of clinical and laboratory findings differential

diagnosis of transient osteoporosis, ischaemic necrosis and infective arthritis were suggested. Subsequently the patient underwent MRI of both hip joints with prior due consent excluding all contraindications as well as explanation regarding how the procedure will be performed.

Patchy areas of T2FS/STIR hyper intensity were present diffusely scattered throughout the bone marrow of femoral head, neck and proximal shaft bilaterally more so on the right side with no evidence of articular cartilage or joint space destruction [Table/Fig-1]. There was also presence of a hypointense fracture line along the medial femoral cortex with



[Table/Fig-1]: Axial PDFS image at level of hip joints showing diffuse hyperintensity involving full thickness of right femoral neck and visualised head (white asterisk) representing marrow oedema.



[Table/Fig-2]: Coronal PDFS image shows a hypointense fracture line (thick white arrow) with surrounding marrow oedema. There is also presence of ipsilateral joint effusion (thin white arrow).

focal cortical bone marrow oedema at the level of fracture line suggestive of stress fracture along with mild ipsilateral joint effusion [Table/Fig-2]. Based on combined clinical, laboratory and imaging findings, diagnosis of transient osteoporosis of hip was made and patient was advised to take rest for four to six weeks duration with minimum weight bearing especially on right lower limb. The patient was prescribed analgesics along with calcium and vitamin D supplement. On the follow-up visit after 6 weeks the patient showed significant symptomatic relief with recovery of full range of motion of affected limb. The patient was not advised repeat MRI in view of significant clinical improvement.

DISCUSSION

TOH is an idiopathic self limited, reversible condition characterized by rapidly developing osteoporosis in the absence of injury, infection or immobilization, showing spontaneous resolution within a year. It is an uncommon disease as well as a diagnosis of exclusion, most often seen in middle age men and minority in women during pregnancy and in early postpartum period [1,2]. MRI is the main diagnostic tool. Radiographs are typically unremarkable but MRI reveals findings consistent with bone marrow oedema invariably. TOH often resembles osteonecrosis with differentiation among these being critical ascribable to differing prognosis and approach to management. A young woman with postpartum status, presented with complaints of difficulty in walking, limited range of motion and pain in right hip. She was diagnosed as a case of TOH on imaging, managed conservatively showing clinical recovery in due course of time. TOH is an idiopathic spontaneous self limited disorder characterized by sudden onset of acute pain in hip, gait disturbance and restricted range of motion with few cases being aggravated by trivial trauma first described in 1959 [3]. Moderate to marked pain aggravated by weight bearing is the most common presentation [4]. The pain peaks at around four to six weeks, resolving within 6-12 months [5].

TOH has a predilection for male gender in approximately two third of cases, mainly seen in 4th-7th decades of life. Women in the third trimester of pregnancy are affected in a minor subset [6]. Moderate to severe pain and difficulty in bearing weight are the most common presentation. The main differential diagnosis of TOH includes avascular necrosis, fracture of neck of femur, infective arthritis, soft tissue injury and inflammatory joint diseases [6]. Laboratory parameters are inconclusive with few cases showing elevated ESR levels [7]. In contrast, femoral osteonecrosis is insidious in onset with functional limitation proportional to the intensity of pain. The etiology of TOH was postulated to be closely related to reflex sympathetic dystrophy and complex regional pain syndrome. All three share common symptomatology however, local skin changes and sympathetic response were not observed in cases of

TOH [7,8]. The etiological factors can be relatively easier to point out in osteonecrosis with systemic corticosteroids and alcohol intake being the main contributors [5].

Conventional radiography is not sensitive with findings lagging behind clinical symptomatology in the majority of cases by a month or two [4,6]. Some cases show diffuse osteopenia of the femoral head and neck, which may become apparent two months post injury. The joint space is preserved invariably in all cases. The pathognomic radiographic finding in cases of TOH is loss of subchondral cortex [7]. Osteonecrosis is idiopathic and has no associated risk factors as with TOH. Early cases will show subchondral sclerosis of the femoral head on plain radiograph [5]. Scintigraphy also plays a role in early diagnosis of TOH being positive before radiographic osteopenia becomes apparent in the form of homogenous femoral head uptake [9]. MRI is the investigation of choice for detecting both TOH and osteonecrosis on the basis of presence or absence of subchondral bony lesion with or without presence of bone marrow oedema, delayed enhancement of abnormal marrow and focal or diffuse nature of disease.

MRI changes in TOH include diffuse bone marrow oedema involving the head and or neck of femur depicted as decrease in bone marrow signal intensity on T1 and increased signal intensity on T2 weighted and fluid sensitive sequences [4]. Presence of hip joint effusion is also a frequent finding [4]. The invariable presence of joint effusion is pointer towards synovial involvement with fluid evaluation being inconclusive [10]. Another frequent finding in TOH is subchondral stress fracture associated with thickening of medial cortex of ipsilateral femoral neck postulated to be a marker of delayed resolution of the disease process [4,8,11]. In case of osteonecrosis there is presence of a focal subchondral defect in the femoral head and the presence of double line/crescent sign most apparent on T2 weighted sequence [6]. Another so called pseudo-homogenous oedema pattern was described by Vande Berg et al with regard to osteonecrosis obscuring the underlying focal pathology [12]. In our case, the involved bone marrow showed T2 hyperintense and T1 hypointense signal showing right hip involvement. No double line was seen, femoral head was normal in outline and morphology with presence of mild joint effusion. There is another closely related entity by name of transient bone marrow oedema syndrome (transient BME) demarcation of which from TOH on conventional radiography and MRI is rather inconsistent, but crucial to avoid unnecessary medical or surgical intervention. In regard to former it was postulated that femoral head core decompression shows rapid relief of symptoms as well as resolution of femoral head oedema [12,13]. It was postulated that MRI has the potential to discriminate between osteonecrosis, TOH and transient BME [12]. Furthermore, it was highlighted that bone marrow oedema appears to be a precursor stage of

osteonecrosis with histological features conforming interstitial bone marrow oedema and no suggestion of osteoporosis [13]. Selected cases undergoing histopathological analysis reveal osteogenesis in response to interstitial oedema and enlargement of medullary sinuses [14].

CONCLUSION

Transient osteoporosis is a rare but well recognised clinical syndrome of unknown etiology requiring greater degree of awareness. Magnetic resonance imaging is the modality of choice for early detection. The disorder is known for spontaneous resolution, albeit delayed response in cases with associated stress fracture. Histopathological evaluation may be required in selected cases to rule out ischaemic necrosis.

REFERENCES

- [1] Gupta P, Sharma S, Gupta V, Singh D, Agarwal A, Chauhan V. Transient osteoporosis of hip-A case report. *Indian J Orthop.* 2005;39:257-59.
- [2] Balakrishnan A, Schemitsch EH, Pearce D, McKee MD. Distinguishing transient osteoporosis of the hip from avascular necrosis. *Can J Surg.* 2003;46(3):187-92.
- [3] Curtiss PH Jr, Kincaid WE. Transitory demineralization of the hip in pregnancy. A report of three cases. *J Bone Joint Surg Am.* 1959;41-A:1327-33.
- [4] Van Wagenen K, Pritchard P, Taylor JA. Transient osteoporosis of the hip: A case report. *J Can Chiropr Assoc.* 2013;57(2):116-22.
- [5] McWalter P, Hassan A. Transient osteoporosis of the hip. *Ann Saudi Med.* 2009;29(2):146-48.
- [6] Rishi V, Wahi P, Mahajan A. Transient osteoporosis of hip (migratory). *JK Science.* 2008;10(4):194-96.
- [7] Hayes CW, Conway WF, Daniel WW. MR imaging of bone marrow edema pattern: transient osteoporosis, transient bone marrow edema syndrome, or osteonecrosis. *Radiographics.* 1993;13:1001-1011; discussion 1012.
- [8] Choudhary MM, Ramesh J, Gupta S. Transient osteoporosis of hip. *J Orthop Allied Sci.* 2015;3:44-47.
- [9] Gaucher A, Colomb JN, Naoun A, Faure G, Netter P. The diagnostic value of 99m Tc-diphosphonate bone imaging in transient osteoporosis of the hip. *J Rheumatol.* 1979;6(5):574-83.
- [10] Berman N, Brent H, Chang G, Honig S. Transient osteoporosis: Not just the hip to worry about. *Bone Reports.* 2016;5:308-311.
- [11] Szwedowski D, Nitek Z, Walecki J. Evaluation of transient osteoporosis of the hip in magnetic resonance imaging. *Pol J Radiol.* 2014;79:36-38.
- [12] Vande Berg BE, Malghem JJ, Labaisse MA, Noel HM, Maldague BE. MR imaging of avascular necrosis and transient marrow edema of the femoral head. *Radiographics.* 1993;13:501-20.
- [13] Hofmann S, Engel A, Neuhold A, Leder K, Kramer J, Plenk H Jr. Bone Marrow oedema syndrome and transient osteoporosis of the hip. An MRI controlled study of treatment by core decompression. *J Bone Joint Surg Br.* 1993;75(2):210-16.
- [14] Patel S. Primary bone marrow oedema syndromes. *Rheumatology.* 2014;53(5):785-92.

AUTHOR(S):

1. Dr. Rahul Dev

PARTICULARS OF CONTRIBUTORS:

1. Assistant Professor, Department of Radiology and Imaging, All India Institute of Medical Sciences, Rishikesh, Uttarakhand, India.

NAME, ADDRESS, E-MAIL ID OF THE CORRESPONDING AUTHOR:

Dr. Rahul Dev,
Assistant Professor, Department of Radiology and Imaging, Ground Floor, Hospital Block, AIIMS, Rishikesh-249203, Uttarakhand, India.
E-mail: rdev8283@gmail.com

FINANCIAL OR OTHER COMPETING INTERESTS:

None.

Date of Publishing: Oct 01, 2018