

# Bilateral Agenesis of Palmaris Longus –A Case Report and its Clinical Significance

JOY A GHOSHAL<sup>1</sup>, PK SANKARAN<sup>2</sup>, TARUN PRAKASH MANRYA<sup>3</sup>, VINAY VISHWAKARMA<sup>4</sup>,  
R MANIVARSHINI<sup>5</sup>, RAGHAVI N MALEPATI<sup>6</sup>

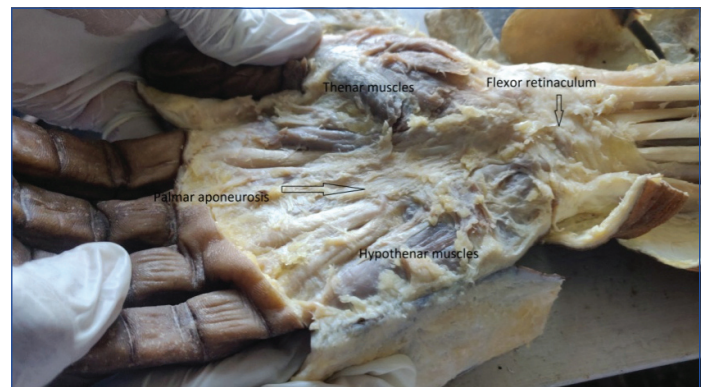
## ABSTRACT

Palmaris longus arises from the medial epicondyle of the humerus and continues as long tendon to get inserted in the apex of flexor retinaculum. The variations of the palmaris longus are common in terms of muscle bellies with additional heads or reversed or absent. This case study shows absent palmaris longus on both sides of the forearm in the cadaver during routine dissection. The agenesis of palmaris longus can be explained due to abnormal division of superficial mass of forearm muscles. The knowledge about this variation is important in terms of reconstructive surgeries utilizing palmaris longus muscle grafts.

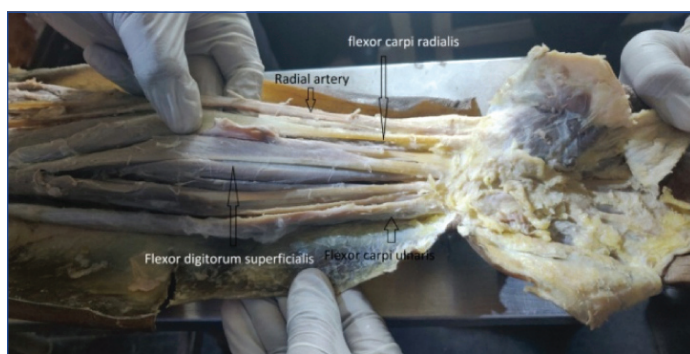
**Keywords:** Muscle grafts, Muscle variations, Tendon reconstruction

## CASE REPORT

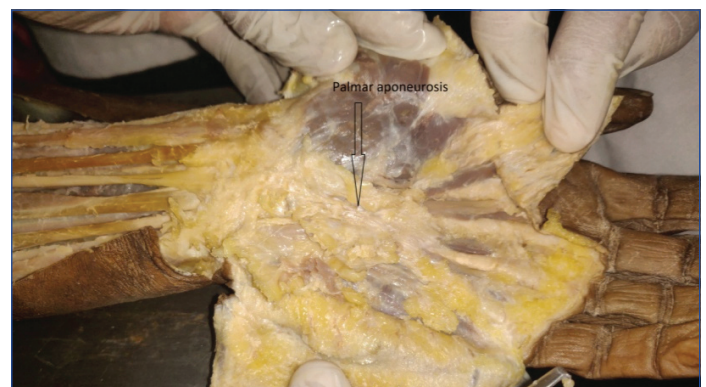
During routine Anatomy dissection in the All India Institute of Medical Sciences, Mangalagiri, in the forearm, there was a variation in the superficial muscles on both limbs. The superficial muscles like Pronator teres, Flexor carpi radialis, flexor digitorum superficialis and flexor carpi ulnaris were originating from the medial epicondyle which is the common flexor origin and inserted into carpal bones and digits without any variation. But the palmaris longus muscle was absent on both sides of the forearm. Absent Palmaris longus in the forearm is shown in [Table/Fig-1-4]. The flexor retinaculum was identified and the palmar aponeurosis was found attached to the distal border of flexor retinaculum. The palmar aponeurosis and the superficial palmar arch didn't show any variations in both hands even with the absence of palmaris longus.



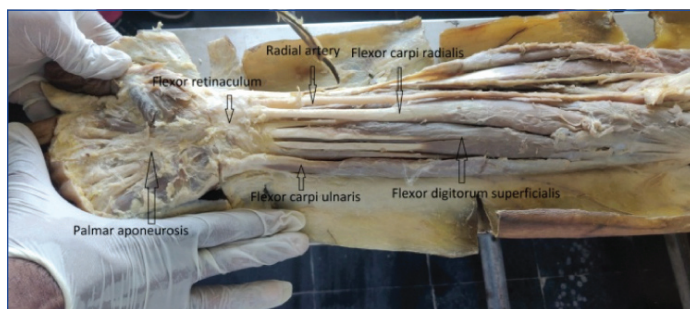
[Table/Fig-3]: Right palm showing palmar aponeurosis.



[Table/Fig-1]: Superficial muscles of left forearm with absent palmaris longus.



[Table/Fig-4]: Left palm with palmar aponeurosis.



[Table/Fig-2]: Superficial muscles of right forearm with absent palmaris longus.

## DISCUSSION

Palmaris longus muscle arises from medial epicondyle along with other superficial flexor muscles and continues as long tendon to

get inserted into apex of palmar aponeurosis and continues as the same. It is supplied by ulnar recurrent artery and median nerve exerting weak flexion of the wrist [1]. There is a growing interest in the variations of this muscle due to its requirement in plastic and reconstructive surgeries involving this muscle tendon. In this study there was bilateral absence of palmaris longus which is one of the common variations. Absent palmaris longus is actually a predictor of abnormal superficial palmar arch [2]; but in this case study there was no superficial palmar arch abnormality. Also, presence of palmaris longus is prone to dupuytren's contracture, absence of this muscle cause less chance [3]. The absent palmaris longus muscle can be tested clinically but it is not a reliable method and magnetic resonance imaging is the only reliable method in individuals needed for tendon replacement [4].

Agenesis of the palmaris longus tendon is the most common variation that has been reported amongst the entire population with higher prevalence in Caucasians. Agenesis of one side is more common than both side and also it is common in women than men [5,6] and it is linked as sex linked dominant trait [7]. The absence of this muscle doesn't affect the grip or flexion of the wrist. Understanding the variation is very important in harvesting grafts for tendon reconstructive surgeries. Its presence in 70-85% population and its superficial location makes it the most common donor material for tendon and joint reconstructive surgeries. The study of length and diameter of the muscle belly makes the harvest easy and reduces the morbidity to the donor site [8]. This tendon can be useful in large number of surgical procedures such as other flexor tendon injuries, ligament reconstructions, ocular defects, reconstruction of thumb and elbow, blepharoptosis.

Variations of palmaris longus are of various types: i) complete absence of muscle; ii) variation in location and morphology of muscle; iii) variation in attachment of the muscle; iv) variation in muscle belly like duplication and triplication; v) addition slips [9]. The variations in the palmaris longus and its actions are functionally negligible, but the knowledge of the variations is very important in reconstructive surgery. A study has described variations in palmaris longus tendon with compressed median nerve. This compression can be due to repeated contraction and hypertrophy of the muscle leading to compartment syndrome [10].

### Embryological Basis of Absence of Palmaris Longus

The flexor muscles of forearm are developed from the forearm mass that divides into two, superficial and deep. The deep derives into flexor digitorum profundus and superficialis, flexor pollicis longus. The superficial mass divides into flexor carpi radialis and ulnaris, pronator

teres and palmaris longus. The agenesis of palmaris longus can be explained by abnormal division of superficial mass of forearm [11].

### CONCLUSION

The knowledge about variations in the palmaris longus muscle is important to Surgeons and Orthopaedicians for reconstruction surgeries and tendon transfer graft in order to prevent surgical complications. The palmaris longus absence and variations can be asymptomatic without affecting strength of movement in flexion of wrist.

### REFERENCES

- [1] Johnson D, Ellis H. Pectoral girdle and upper limb. In: Standring S, ed. Gray's Anatomy. 41<sup>th</sup> Ed., Edinburgh, Elsevier Churchill Livingstone. 2016; 876-877.
- [2] O'Sullivan E, Mitchell BS. Association of the absence of palmaris longus tendon with an anomalous superficial palmar arch in the human hand. *J Anat.* 2002;201:405.
- [3] Powell BW, McLean NR, Jeffs JV. The incidence of a palmaris longus tendon in patients with Dupuytren's disease. *J Hand Surg Br.* 1986;11:382-84
- [4] Teh J, Whiteley G. MRI of soft tissue masses of the hand and wrist. *Br J Radiol.* 2007;80:47-63.
- [5] Reimann AF, Daseler EH, Anson BJ, Beaton LE. The palmaris longus muscle and tendon: A study of 1600 extremities. *Anat.* 1944;89:495-505.
- [6] Park MJ, Namdari S, Yao J. Anatomic variations of the palmaris longus muscle. *Am J Orthop (Belle Mead NJ).* 2010;39:89-94.
- [7] Gangata H. The clinical surface anatomy anomalies of the palmaris longus muscle in the black African population of Zimbabwe and a proposed new testing Technique. *Clin Anat.* 2009;22:230-35.
- [8] Sebatin SJ, Lim AY, Bee WH, Wong TC, Methil BV. Does the absence of the Palmaris longus affect grip and pinch strength? *J Hand Surg Br.* 2005;30:406-08.
- [9] Prathap K, Prakash S, Padmalatha K, Ramesh B. Duplication of palmaris longus. *Int J Anat Var (IJAV).* 2013;6:207-09.
- [10] Blackhouse KM, Churchill-Davidson D. Anomalous palmaris longus muscle producing carpal tunnel-like compression. *Hand.* 1975;7:22-24.
- [11] Kumar V, Naveen NS, Murlimanju BV, D'souza PS. A rare muscular variation in the flexor compartment of the forearm. *Int J Anat Var (IJAV).* 2011;4:115-16.

#### PARTICULARS OF CONTRIBUTORS:

1. Professor, Department of Anatomy, All India Institute Medical Sciences, Mangalagiri, Andhra Pradesh, India.
2. Associate Professor, Department of Anatomy, All India Institute Medical Sciences, Mangalagiri, Andhra Pradesh, India.
3. Student, All India Institute Medical Sciences, Mangalagiri, Andhra Pradesh, India.
4. Student, All India Institute Medical Sciences, Mangalagiri, Andhra Pradesh, India.
5. Student, All India Institute Medical Sciences, Mangalagiri, Andhra Pradesh, India.
6. Student, All India Institute Medical Sciences, Mangalagiri, Andhra Pradesh, India.

#### NAME, ADDRESS, E-MAIL ID OF THE CORRESPONDING AUTHOR:

Dr. PK Sankaran,  
Department of Anatomy, All India Institute of Medical Sciences, Temporary Campus Siddhartha Medical College,  
Mangalagiri, Andhra Pradesh, India.  
E-mail: drpks@live.com

FINANCIAL OR OTHER COMPETING INTERESTS: None.

Date of Submission: **Dec 24, 2018**

Date of Peer Review: **Jan 23, 2019**

Date of Acceptance: **Feb 02, 2019**

Date of Publishing: **Apr 01, 2019**