

# High Resolution Computed Tomography in the Diagnosis of Pulmonary Tuberculosis and its Correlation with Sputum/ Bronchoalveolar Lavage Analysis

HARSH LATHIYA<sup>1</sup>, PRABHAT DEBBARMA<sup>2</sup>, JAYBRATA RAY<sup>3</sup>, ANJAN DAS<sup>4</sup>



## ABSTRACT

**Introduction:** Pulmonary Tuberculosis (PTB) is one of the major health related burden in the entire country. Clinicians face dilemma whether to start antitubercular treatment or not in sputum negative patients. In equivocal or negative microbiological results High Resolution Computed Tomography (HRCT) can be helpful tool to guide physicians whether or not to start the treatment in patients with suspicion of active PTB.

**Aim:** To assess the accuracy of HRCT in diagnosis and evaluation of disease activity in PTB and to correlate the findings of HRCT with Acid-Fast Bacilli (AFB) smear & culture results.

**Materials and Methods:** An observational study was conducted between August 2015 to August 2017, in which fifty patients with suspected PTB were included into the study. HRCT thorax and Sputum/Bronchoalveolar Lavage (BAL) AFB smear & culture tests were performed for each of these patients. The pattern, extent and severity of HRCT features were assessed and results correlated with sputum/BAL AFB findings. Active tuberculosis was confirmed when smear and/or culture of AFB in sputum or lavage fluid are positive and/or when follow-up HRCT showed radiological improvement with antituberculous chemotherapy. The statistical tests were applied and analysed using appropriate

statistical software Statistical Package for Social Sciences (SPSS) version 16. The chi square test was used to determine the association and p-value <0.05 was considered to be significant. A p-value <0.05 was considered statistically significant.

**Results:** Mean age was 36.3±3.18 years. The most frequent CT patterns of active disease, present as isolated or mixed findings, were centrilobular nodules (73%), tree-in-bud opacities (59%) and larger nodules (54%). Distribution of the HRCT findings was noted to be more common in apical segments of upper lobes and superior segments of lower lobes. High Resolution CT showed high diagnostic accuracy (94%). Active (35/37, 94.5%) and inactive (12/13, 92.3%) state could be correctly differentiated by HRCT. Sensitivity, specificity, Positive Predictive Value (PPV) and Negative Predictive Value (NPV) HRCT were calculated to be 97.22%, 85.71%, 94.59% and 92.31%.

**Conclusion:** This study concludes that HRCT is a powerful and reliable investigation in the diagnosis of tuberculosis and determination of its disease activity, when other means of diagnosis such as sputum/BAL AFB test and Culture fail to settle the matter, are not available or time consuming and should be routinely indicated in sputum smear negative patients for prompt initiation of antitubercular treatment.

**Keywords:** AFB, Culture, Disease activity, Radiology, Smear

## INTRODUCTION

Pulmonary Tuberculosis (PTB) is a common problem in developing countries particularly among the lower socioeconomic group. Despite all governmental efforts, it still remains a major public health problem and is major contributor to global TB burden [1].

At present, the diagnostic guidelines of PTB are primarily based on the demonstration of AFB on sputum microscopy and Chest X-ray findings [2].

The delay in diagnosis results in delay in therapy with more chance for spread of infection and increase in severity of the disease [3].

Sputum test still faces inherent limitations of decreased load of bacilli, inability to produce sputum, saliva given instead of sputum and few days to get the results. The gold standard for diagnosis of Mycobacteria TB is Culture but it needs up to 6 weeks for results. There are new radiometric cultures which need about 2 weeks to give results however these are not available in every hospital [4].

Chest radiography is the imaging modality of choice in the initial evaluation of patients with suspected pulmonary infection and in monitoring response to the therapy [5].

HRCT is more sensitive than chest radiography in the detection, characterisation & distribution of both subtle parenchymal disease [5-7]. HRCT is helpful in the differential diagnosis of TB from other lung

diseases, in the distinction of active from inactive TB, in determining the degree of smear positivity, and in assessing antituberculous treatment efficiency [8-10]. HRCT has some demerits such as added cost and higher radiation as compared to chest X-ray, but in equivocal or indeterminate cases it can identify active tuberculosis even if the chest radiograph is negative [11].

PTB is one of the major health related burden in the entire country and even in the regional population. Though Computed Tomography (CT) is often engaged in the diagnosis and follows up of TB, it does not find a place in the national and international guidelines. Literature is deficient and no agreement exists on use of HRCT in such patients. With India having a large load of TB, it is significant to have well-known imaging criteria and recommendations [2]. Hence, present study was conducted with an aim to assess the accuracy of HRCT in diagnosis and evaluation of disease activity in PTB and to correlate the findings of HRCT with AFB smear & culture results.

## MATERIALS AND METHODS

This was an observational study conducted in the department of Radio-Diagnosis, Agartala government Medical College and GB Pant Hospital. It was approved by the Ethics Review Board of the institution {F4(5-192/AGMC/Academic/IRC & IEC meeting/2015}.

The subjects of this study provided written informed consent prior to their inclusion.

Patients with clinical suspicion of PTB attending the Radio-diagnosis Department between August 2015 to August 2017, were the target population if they fulfilled the inclusion and exclusion criteria. These patients were referred from various departments, especially from General Medicine and Respiratory Medicine departments.

### Inclusion Criteria

1. Patients clinically suspected with PTB, with or without positive chest radiograph findings, and 2 sputum AFB examinations/ BAL and positive/negative for tuberculosis.
2. Patients even with immunocompromised status.
3. Patients of any gender and age.

### Exclusion Criteria

1. Pregnant women
2. Patients or parents of children unwilling to take part in the study.

All the patients who qualify the inclusion criteria underwent HRCT Thorax scan on CT machine, manufacturer PHILIPS, model BRILLIANCE 16 and sequential axial slices of 1 mm thickness were obtained from the lung apex to the base with the patients in supine position. The HRCT was performed using the imaging protocol: 0.5 s rotation time, pitch 0.81; 120 kV, sure exposure standard mA, 1 mm slice thickness. No intravenous contrast was administered to the patients.

All the patients which fit the inclusion criteria also underwent sputum smear reports for AFB and/or BAL AFB reports within an interval of one week from the HRCT scan. Mycobacterial cultures of all the specimens were performed on both Löwenstein-Jensen solid medium and in the BACTEC MGIT 960 liquid culture system. A Gram stain and microorganism identification was performed in all the samples according to standard protocols to exclude pulmonary infections other than PTB.

The patients who tested AFB positive were treated with full course of Anti-tuberculosis treatment for six months. HRCTs were performed at the beginning of the treatment and at the end of the treatment to assess resolution of radiological findings.

The patients who tested AFB negative were treated with routine broad spectrum antibiotics excluding antituberculous chemotherapeutic agents to rule out any non-tuberculous pulmonary infections and only if the symptoms did not resolve and there was still clinical suspicion of pulmonary TB, antituberculous treatment was started. HRCT Thorax was performed at the start of treatment and then at third month while on treatment during follow-up. Those patients with negative cultures had thorough clinic-radiological work-up at third month to evaluate if there had been any attributable response to antituberculous chemotherapy. In such patients, where there was no such response attributable to antituberculous medications, treatment was stopped and efforts were made to enquire about any available known history of previous tuberculosis which could be a pointer to these lesions being considered as inactive or sequelae. The rest of the patients which showed response attributable to antituberculous medications completed the six month course which consisted of two-month initial phase of rifampicin, isoniazid, pyrazinamide and ethambutol, and a four-month maintenance phase of rifampicin and isoniazid via Directly Observed Treatment Short-course (DOTS).

The HRCT images were assessed in lung window by two radiologists, who were blinded to clinic-microbiological results, and following parameters were recorded. In case of any discrepancy, final agreement reached between two radiologists was considered.

The HRCT images were analysed for the morphology, number and lobar distribution of pulmonary lesions. Parameters which were

noted include centrilobular nodule (discrete, 5-10 mm, round, focal nodular opacity located centrally within secondary pulmonary lobule), tree-in-bud pattern (multiple centrilobular nodules in linear branching pattern), large nodule (rounded or irregular opacity, well or poorly defined, measuring 3 mm to 3 cm in diameter), patchy unilateral or bilateral air-space consolidation, frequently peribronchial in distribution, cavitation, miliary disease, pleural effusion/empyema, low density hilar/mediastinal lymph nodes, fibrosis +/- Traction bronchiectasis/bronchiolectasis, calcified nodule, pleural thickening and peri-cicatricial emphysema

### STATISTICAL ANALYSIS

The data was entered in master chart and statistical tests were applied and analysed using appropriate statistical software (SPSS 16 statistical package). The chi-square test was used to determine the association and p-value <0.05 was considered to be significant.

### RESULTS

There were a total of 50 patients. This study consists of 38 male and 12 female patients (Total 50 patients) aged 18-80 years with mean age of 36.3±3.18 years. There was no statistically significant difference in the mean age between the groups and subgroups (p>0.05).

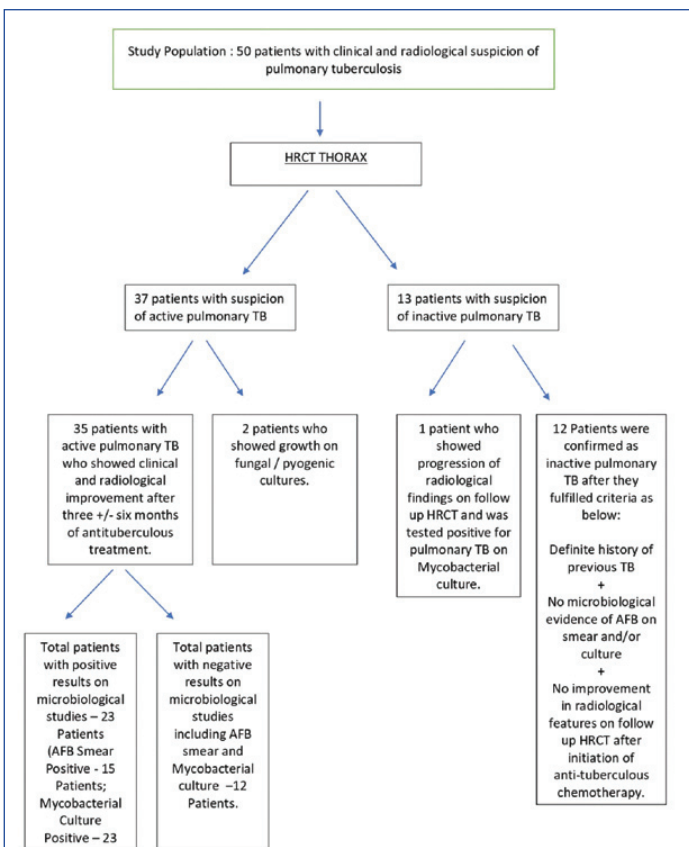
On the basis of findings on HRCT Thorax at the beginning of treatment, these patients were classified into two main groups - 37 patients with suspicion of active pulmonary TB (Group I) and 13 patients with suspicion of inactive pulmonary TB (Group II). Thirty five patients in Group I showed radiological and clinical improvement on follow-up scan after three and/or six months of treatment (Subgroup IA). Two patients in Group I showed growth on fungal/ pyogenic cultures (Subgroup IB). Twelve patients in Group II did not have radiological and clinical improvement on three month follow-up and were considered to be inactive or sequelae and the treatment was stopped in these patients (Subgroup IIA). One patient in Group II showed progression of radiological findings on three month follow-up HRCT and showed growth on Mycobacterial culture which suggested active pulmonary TB and went on to have complete course of six month antituberculous chemotherapy (Subgroup IIB).

In Group I patients, sputum/BAL AFB smear examination was positive in 15 patients and mycobacterial culture examination was positive in 23 patients (Subgroup IA) and sputum/BAL AFB smear examination was negative in 20 patients and mycobacterial culture examination was negative in 12 patients (Subgroup IB). In Group II, 12 patients did not show any AFB on sputum/BAL smear examination or any growth on mycobacterial culture (Subgroup IIA), while 1 patient showed growth on mycobacterial culture (Subgroup IIB). No patients in the present study population were HIV positive. These has been summarised in [Table/ Fig-1].

Most common symptom in this study was recorded to be cough, being present in 76% of patients, followed by sputum production in 64%, evening rise of temperature in 52% and haemoptysis in 32% of patients. There were no statistically significant differences in symptoms between the two groups (p>0.05) using chi-square test [Table/Fig-2].

The most common HRCT findings in Group I were centrilobular nodules, tree in bud opacities, and larger nodules. Miliary nodules were observed in two patients in the present study. There was no statistically significant difference in the findings between Group IA and Group IB (p>0.05) using chi-square test [Table/Fig-3].

The most common HRCT findings in Group II were fibrosis +/- traction bronchiectasis/bronchiolectasis and calcified nodules. There was statistically significant difference in the HRCT findings between Group I and Group II. p-value was calculated using Chi-square test and was significant (0.003) [Table/Fig-4].



[Table/Fig-1]: Summarised flowchart of patients

Clinical Parameters	Group I (N=37)	Group II (N=13)	p-value
Cough	28	10	0.501
Sputum	22	10	0.562
Evening rise in temperature	16	4	0.086
Haemoptysis	13	3	0.746

[Table/Fig-2]: Group-wise distribution of clinical parameters. Chi-square test

HRCT Parameters in Active Pulmonary TB (Group I)	N(%) (Total patients in Group I - 37)
Centrilobular nodules	28 (73%)
Tree-in-bud opacities	23 (59%)
Larger nodules	20 (54%)
Consolidation	18 (48%)
Cavitation	16 (43%)
Ground glass opacities	7 (20%)
Mediastinal lymphadenopathy with low density centres	5 (14%)
Pleural effusion/Empyema	11 (30%)

[Table/Fig-3]: HRCT Parameters in patients with Active pulmonary TB (Group - I).

HRCT Parameters in Inactive/sequelae of pulmonary TB (Group - II)	N(%) (Total patients in Group II - 13)
Fibrosis with Traction bronchiectasis	10(77%)
Calcification	4(30%)
Pleural thickening	4(30%)
Pericatricral emphysema	4(30%)

[Table/Fig-4]: HRCT Parameters in patients with Inactive/sequelae of pulmonary TB (Group - II).

The predominant involvement of both upper lobes (Right > Left) was seen [Table/Fig-5].

Crosstab demonstrates Sputum/ Bronchoalveolar lavage AFB results and final results correlation which reveals that out of total 36

positive (active PTB) cases, 15 were correctly detected and 21 were missed i.e., false negative [Table/Fig-6].

Crosstab demonstrates Mycobacterial culture results and final results correlation which reveals that out of total 36 positive (active PTB) cases, 24 were correctly detected and 12 were missed i.e., false negative [Table/Fig-7].

	Group I - N=37 (%)	Group II- N=13 (%)
Right upper lobe	27 (73%)	11 (84%)
Right middle lobe	18 (48%)	5 (38%)
Right lower lobe	20 (54%)	7 (54%)
Left upper lobe	22 (59%)	10 (76%)
Left lower lobe	15 (40%)	3 (23%)

[Table/Fig-5]: Distribution of radiological lesions in lung lobes

	Result		Total
	Positive (Active Pulmonary TB) (Group I)	Negative (Inactive Pulmonary TB/Alternate diagnosis) (Group II)	
Sputum /BAL Positive	15	0	15
AFB Negative	21	14	35
Total	36	14	50

[Table/Fig-6]: Comparative analysis and Correlation of final outcome with results obtained from sputum /Bronchoalveolar Lavage (BAL) AFB smear

	Result		Total
	Positive (Active Pulmonary TB) (Group I)	Negative (Inactive Pulmonary TB/Alternate diagnosis) (Group II)	
Culture Positive	24	0	24
Negative	12	14	26
Total	36	14	50

[Table/Fig-7]: Comparative analysis and Correlation of final outcome with results obtained from Mycobacterial culture

Crosstab demonstrates HRCT thorax results and final results correlation which reveals that out of total 36 positive (active PTB) cases, 35 were correctly detected, two were incorrectly detected i.e., false positive and one case was missed i.e., false negative [Table/Fig-8].

	Result		Total
	Positive (Active Pulmonary TB) (Group I)	Negative (Inactive Pulmonary TB/Alternate diagnosis) (Group II)	
HRCT Thorax Positive	35	2	37
Negative	1	12	13
Total	36	14	50

[Table/Fig-8]: Comparative analysis and Correlation of final outcome with results obtained from HRCT Thorax

The HRCT findings recorded in the present study are presented in [Table/Fig-9-11].

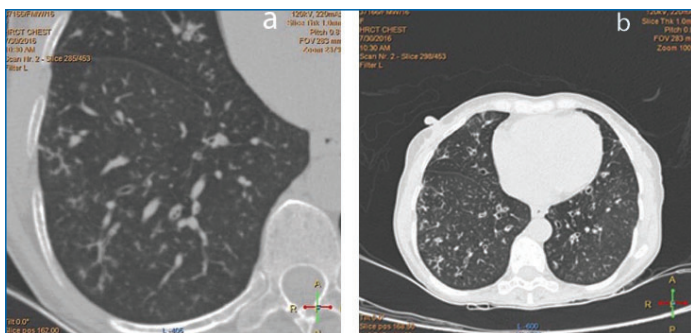
Sensitivity, specificity, PPV and NPV of HRCT were calculated to be 97.22%, 85.71%, 94.59% and 92.31% [Table/Fig-12].

## DISCUSSION

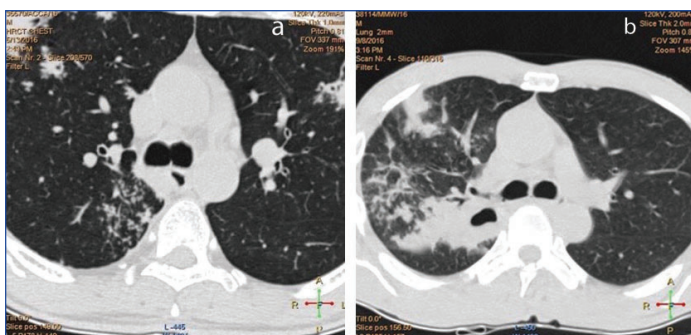
In present study, the role of HRCT in diagnosis of pulmonary TB and determination of disease activity status was determined.

The common clinical features noted were cough and sputum production followed by evening rise in temperature and haemoptysis. Cough was also reported as the most common symptom in active PTB by various authors [7,12,13]. There was no statistically

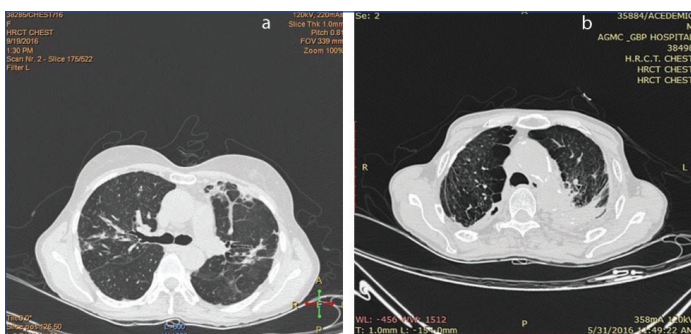




**[Table/Fig-9]:** (a) Axial HRCT Image below the level of carina shows multiple centrilobular nodules and tree-in-bud opacities in right lower lobe; (b) Zoomed view of the above image clearly depicts the.



**[Table/Fig-10]:** a) Magnified image of Axial HRCT at the level of carina shows multiple centrilobular nodules and branching "tree-in-bud" opacities in superior segment of right lower lobe. Larger nodules are also seen in both upper lobes; b) Axial HRCT image at the level of carina shows multiple poorly defined areas of consolidation and cavitation within superior segment of right lower lobe. Multiple centrilobular nodules, tree-in-bud opacities and larger nodules are also seen in right upper lobe.



**[Table/Fig-11]:** a) Axial HRCT image at the level of carina shows multiple irregular, linear and streaky areas of fibrosis and associated traction bronchiectasis in both upper lobes; b) Axial HRCT image at the level of lung apices shows areas of pericardial emphysema, fibrosis and calcified pleural thickening in both lung apices.

	Sputum/ BAL AFB smear	Mycobacterial culture	HRCT thorax	p-value
Sensitivity	41.67 %	66.67%	97.22%	*p<0.001
Specificity	100%	100%	85.71%	
Positive predictive value	100%	100%	94.59%	
Negative predictive value	40%	53.85%	92.31%	
Positive likelihood ratio	∞	∞	6.81	
Negative likelihood ratio	0.58	0.33	0.03	
Accuracy	58%	76%	94%	

**[Table/Fig-12]:** Summary of statistical parameters recorded in this study. [ $p < 0.001$ ]. Chi-square test was used

significant difference to differentiate active PTB from inactive PTB based on clinical symptoms in this study.

The chest radiograph has poor specificity for detection of pulmonary TB, which may be better dealt with by HRCT [6,14]. Lee SW et al., calculated the use of CT in examination of TB outbreak and

with the use of CT they could make a diagnosis of active TB in nine patients who had normal chest X-ray and they concluded that adding up CT to custom investigation of TB outbreak may be useful in differentiating active TB from Latent TB infection [11].

In present study, out of 50 patients with PTB, 48 were correctly diagnosed (96%) and two patients (4%) were incorrectly diagnosed, on the basis of HRCT findings. The two incorrectly diagnosed cases were later proven to be having fungal aspergillosis and bacterial pneumonia on microbiological studies, respectively.

The most frequent CT patterns of active PTB disease, present as isolated or mixed findings, were centrilobular nodules, tree-in-bud opacities and larger nodules. Centrilobular nodules consist of solid caseous material within or around the terminal or respiratory bronchioles which constituted major findings seen in active Pulmonary TB in the present study. Centrilobular nodules are known as acute inflammatory lesions and are one of the radiological lesions showing active PT [15]. Tree-in-bud patterns on CT were first used by Im JG et al., for the endobronchial spread of PTB. The tree-in-bud pattern is thought to be a reliable criterion for active disease, but not pathognomonic for active PTB [16]. The presence of centrilobular nodules were the most common HRCT finding in active PTB patients in various studies [9,17,18]. The tree-in-bud pattern, suggestive of endobronchial spread, and hence active disease, was the most common and characteristic of the findings on HRCT as reported by Raniga S et al., [6].

The other radiological findings which were observed in active PTB patients were poorly defined areas of consolidation, cavitation, mediastinal lymphadenopathy, miliary nodules and pleural effusion/empyema. These findings also compared with those observed by various authors [7,9,17,15]. Im JG et al., observed that cavities are formed when the caseous necrotic material liquefies and is extruded through the connecting airway [16]. The presence of a cavity is an important sign that indicates active disease [19].

There was predilection for apical segments of upper lobes and superior segments of lower lobes in patients with active PTB in the present study. Similar predilection for distribution of radiological findings was also observed in patients with active PTB by Okutan O et al., [20].

The most frequent CT findings in the present study in inactive PTB, being present alone or mixed, were areas of fibrosis & traction bronchiectasis, pericardial emphysema, calcified granulomata and pleural thickening.

This is in concordance with findings of Millen WT and MacGregor RR who emphasised that these findings suggest radiographic stability or inactive disease [13]. Similar findings were observed in study by Lee KS et al., which noted that calcified nodule, irregular lines, parenchymal bands, and pericardial emphysema are the unique findings that can be observed only in the patients with inactive PTB and not in any with active disease [21].

In present study, the sputum smear for AFB and culture had low sensitivity and low negative predictive value as compared to HRCT. The sensitivity of sputum smear for AFB ranges from 46 to 74%, whereas that of sputum culture ranges from 82 to 95% while specificity of both smear and culture is more than 98% [22-24]. The results of these studies are in agreement with present study results.

The yield of sputum culture for detecting AFB is higher than that of direct sputum smear. The delay (usually six to eight weeks) in obtaining results for AFB culture remains a problem. In this situation, CT may enable presumptive diagnosis of PTB and beginning empiric chemotherapy.

### Limitation(s)

One of the limitations in present study was the lack of HIV positive patients, which have high prevalence of active PTB [25]. The findings

in HIV positive patients may be different and may complicate matters if misdiagnosed as Smear/Culture negative active PTB and hence this limitation needs to be taken in mind while interpretation of HRCT findings in the cohort of HIV positive patients [26]. Reader experience and limited sample size are also another limitations in present study.

## CONCLUSION(S)

HRCT is a powerful and reliable investigation in the diagnosis of tuberculosis and determination of its disease activity, when other means of diagnosis such as sputum/BAL AFB test and culture fail to settle the matter, are not available or time consuming and should be routinely indicated in sputum smear negative patients for prompt initiation of antitubercular treatment. Centrilobular nodules, tree-in-bud appearance and cavitation are best indicators of active disease. Fibrosis with Traction bronchiectasis, pleural thickening and calcified granulomas are indicators of inactive disease. This study concludes that HRCT is a useful tool in the diagnosis and management as it can differentiate active from inactive disease with greater sensitivity.

## REFERENCES

- [1] Treatment of Tuberculosis: Guidelines, fourth edition, WHO/HTM/TB/2009:15-18
- [2] Bhalla AS, Goyal A, Guleria R, Gupta AK. Chest tuberculosis: Radiological review and imaging recommendations. *Indian J Radiol Imaging*. 2015;25:213-25.
- [3] Shaarawy H, Zeidan M, Nasr A. Assessment of the role of high resolution computed tomography in the diagnosis of suspected sputum smear negative active pulmonary TB Egypt *J Chest Dis Tuberc*. 2013;62:263-68.
- [4] Foulds J, O'Brien R. New tools for the diagnosis of tuberculosis: the perspective of developing countries *Int J Tuberc Lung Dis*. 1998;2(10):778-83.
- [5] Bolla S, Bhatt C, Shah D. Role of HRCT in predicting disease activity of pulmonary tuberculosis. *GMJ*. 2014;69(2):91-95.
- [6] Raniga S, Parikh N, Arora A, Vaghani M, Vora PA, Vaidya V. Is HRCT reliable in determining disease activity in pulmonary tuberculosis? *Indian J Radiol Imaging*. 2006;16:221-28.
- [7] Nakanishi M, Demura Y, Ameshima S, Kosaka N, Chiba Y, Nishikawa S, et al. Utility of High resolution computed tomography for predicting risk of sputum smear negative pulmonary tuberculosis. *Eur J Radiol*. 2010;73(3):545-50.
- [8] Ors F, Deniz O, Bozlar U, Gumus S, Tasar M, Tozkoparan E, et al. High-resolution CT findings in patients with pulmonary tuberculosis: correlation with the degree of smear positivity. *J Thoracic Imaging*. 2007;22:154-59.
- [9] Hatipo lu ON, Osma E, Manisali M. High resolution computed tomographic findings in pulmonary tuberculosis. *Thorax*. 1996;51(4):397-402.
- [10] Poey C, Giron J, Verhaegen F, Levenes H, Gruels S, Fajadet P, et al. High resolution chest CT in tuberculosis: evolutive patterns and signs of activity. *J Comput Assist Tomogr*. 1997;21(4):601-07.
- [11] Lee SW, Jang YS, Park CM, Kang HY, Koh WJ, Yim JJ, et al. The role of chest CT scanning in TB outbreak investigation. *Chest*. 2010;137(5):1057-64.
- [12] Caliskan T, Ozkisa T, Aribal S. High resolution computed tomography findings in smear- negative pulmonary tuberculosis patients according to their culture status. *J Thorac Dis*. 2014;6(6):706-12.
- [13] Miller WT, MacGregor RR. Tuberculosis: frequency of unusual radiographic findings. *American Journal of Roentgenology*. 1978;130:867-75.
- [14] Wang YH, Lin AS, Lai YF, Chao TY, Liu JW, Ko SF. The high value of high-resolution computed tomography in predicting the activity of pulmonary tuberculosis. *Int J Tuberc Lung Dis*. 2003;7:563-68.
- [15] Lee JJ, Chong PY, Lin CB, Hsu AH, Lee CC. High resolution chest CT in patients with pulmonary tuberculosis: characteristic findings before and after antituberculous therapy. *Eur J Radiol*. 2008;67:100-04.
- [16] Im JG, Itoh H, Shim YS, Lee JH, Ahn J, Han MC, et al. Pulmonary tuberculosis: CT findings- early active disease and sequential change with antituberculous therapy. *Radiology*. 1993;186:653-60.
- [17] Tozkoparan E, Deniz O, Ciftci F, Bozkanat E, Bicak M, Mutlu H et al. The roles of HRCT and clinical parameters in assessing activity of suspected smear negative pulmonary tuberculosis. *Arch Med Res*. 2005;36:166-70.
- [18] Kosaka N, Sakai T, Uematsu H, Kimura H, Hase M, Noguchi M, et al. Specific high resolution computed tomography findings associated with sputum smear-positive pulmonary tuberculosis. *J Comput Assist Tomogr*. 2005;29:801-04.
- [19] Jeong YJ, Lee KS. Pulmonary tuberculosis: up-to-date imaging and management. *Journal of Roentgenology*. 2008;191:834-44.
- [20] Okutan O, Tas D, Demirel E, Ciftci F, Kartaloglu Z. The clinical and radiological features of patients with smear and culture-negative pulmonary tuberculosis requiring histopathological examination. *Turk Gogus Kalp Damar Cerrahisi Dergisi-Turkish Journal of Thoracic And Cardiovascular Surgery*. 2012;20:572-76.
- [21] Lee KS, Im JG. CT in adults with tuberculosis of the chest: Characteristic findings and role in management. *AJR Am J Roentgenol*. 1995;164:1361-67.
- [22] Levy H, Feldman C, Sacho H, van der Meulen H, Kallenbach J, Koornhof H. A reevaluation of sputum microscopy and culture in the diagnosis of pulmonary tuberculosis. *Chest*. 1989; 95:1193-97.
- [23] Gordin F, Slutkin G. The validity of acid-fast smears in the diagnosis of pulmonary tuberculosis. *Arch Pathol Lab Med*. 1990;114:1025-27.
- [24] Kim TC, Blackman RS, Heatwole AM. Acid-fast bacilli in sputum smears of patients with tuberculosis: prevalence and significance of negative smears pretreatment and positive smears post-treatment. *Am Rev Respir Dis*. 1984;129:264-70.
- [25] Siddiqi K, Lambert ML, Walley J. Clinical diagnosis of smear-negative pulmonary tuberculosis in low-income countries: the current evidence. *Lancet Infect Dis*. 2003;3:288-96.
- [26] Colebunders R, Bastian I. A review of the diagnosis and treatment of smear-negative pulmonary tuberculosis. *Int J Tuberc Lung Dis*. 2000;4:97-107.

### PARTICULARS OF CONTRIBUTORS:

1. Department of Radiodiagnosis, Agartala Government Medical College and GB Pant Hospital Agartala, Tripura, India.
2. Department of Radiodiagnosis, Agartala Government Medical College and GB Pant Hospital Agartala, Tripura, India.
3. Department of Radiodiagnosis, Agartala Government Medical College and GB Pant Hospital Agartala, Tripura, India.
4. Department of Respiratory Medicine, Agartala Government Medical College and GB Pant Hospital Agartala, Tripura, India.

### NAME, ADDRESS, E-MAIL ID OF THE CORRESPONDING AUTHOR:

Harsh Lathiya,  
20, Devpriya Bungalows- Part 2, 100 Ft Road, Satellite, Ahmedabad, Gujarat, India.  
E-mail: harsh.lathiya@gmail.com

### AUTHOR DECLARATION:

- Financial or Other Competing Interests: None
- Was Ethics Committee Approval obtained for this study? Yes
- Was informed consent obtained from the subjects involved in the study? Yes
- For any images presented appropriate consent has been obtained from the subjects. Yes

### PLAGIARISM CHECKING METHODS: [Jain H et al.]

- Plagiarism X-checker: Jun 01, 2020
- Manual Googling: Jul 25, 2020
- iThenticate Software: Sep 22, 2020 (06%)

### ETYMOLOGY: Author Origin

Date of Submission: **May 31, 2020**

Date of Peer Review: **Jun 19, 2020**

Date of Acceptance: **Jul 27, 2020**

Date of Publishing: **Oct 01, 2020**