

Medial Cutaneous Nerve of Axilla-A Rare Cutaneous Branch of Medial Cord of Brachial Plexus

AVINASH THAKUR, ASHUTOSH ANSHU, VANDANA MEHTA, RAJESH KUMAR SURI, GAYATRI RATH

ABSTRACT

Precise anatomical knowledge of brachial plexus formation, its branching pattern and the possible variations are extremely important for effective brachial plexus blockade while performing upper limb procedures. Though anomalies of brachial plexus are well documented in the medical literature, this case report documents a unique cutaneous branch of the medial cord of brachial plexus which was found innervating the superior part of the medial wall of the

axilla and hence was named as the Medial cutaneous nerve of axilla. Variations in the dermatomal pattern of the human body are extremely rare. In this report we document a variant dermatomal distribution of the medial wall of axilla coming from the C8 and T1 spinal segments in the form of the medial cutaneous nerve of axilla. Cutaneous innervation of the upper limb and the axillary walls is of utmost importance in raising cutaneous flaps during reconstructive oncogenic surgeries.

Key Words: Brachial plexus, Medial cord, Flap reconstruction, Dermatome, Axilla

INTRODUCTION

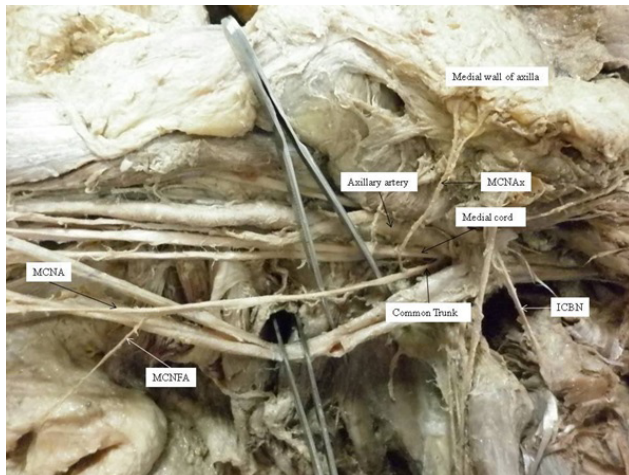
The brachial plexus is situated in the posterior triangle of the cervical region and in the axilla. This plexus is a union of the lower four cervical (C5, C6, C7, and C8) ventral rami and the first thoracic (T1) ventral ramus. At the lateral border of the anterior scalene muscle, the five roots unite to form the upper, middle, and lower trunks, each of which splits into anterior and posterior divisions in the floor of the posterior triangle of the neck. At the upper border of the first rib, the divisions join to form lateral, medial and posterior cords. Just distal to the inferior border of the pectoralis minor muscle, near the third part of the axillary artery, the cords give off their terminal branches [1-4]. Knowledge of peripheral nerve supply of upper limb, contributed by the brachial plexus is of immense surgical importance. Multiple number of variations in the brachial plexus have been reported in the literature. Surgical anatomy of these anomalies of brachial plexus have become extremely significant because of emergence of brachial plexus blockade as a novel technique in performing many surgical and anaesthetic procedures in the region of upper limb and axilla. Abnormalities in the brachial plexus and brachial plexopathies result from problems of the cervicothoracic vertebrae and the soft tissue in that region [5]. Precise knowledge of dermatomal supply of the axilla becomes extremely important in cases of tumours of the breast where radical clearance of the axilla and flap reconstruction is required. During routine dissection

of the axilla we found a rare branch of medial cord of brachial plexus which innervated the superior part of the medial wall of the axilla.

CASE REPORT

The present variation was found during routine educational dissection of a 60 year old cadaver in Vardhaman Mahavir Medical College-New Delhi, India. The region of neck and axilla was dissected to expose the formation and branching pattern of the brachial plexus. The formation of brachial plexus was found to be normal on both sides. In the right upper limb, the medial cutaneous nerve of arm and the medial cutaneous nerve of forearm originated from a common trunk which was arising from the medial cord of brachial plexus. This common trunk divided into the two terminal cutaneous branches for the arm and the forearm 12 centimetres distal to its origin from the medial cord. Further, this common trunk gave off an additional cutaneous branch that coursed medially towards the superior part of the medial wall of the axilla. The point of origin of this additional branch was located 2.3 centimetres distal to the origin of the common trunk and 3.6 centimetres distant from the right coracoid process. It was related inferiorly to the intercostobrachial nerve which was seen piercing the second intercostal space. This variant branch innervated the skin of the medial wall of axilla in the region of the first intercostal space along with the lateral cutaneous branch of

the first intercostals nerve [Table/Fig-1]. This variant branch had no communication with the intercostobrachial nerve or the lateral cutaneous branch of the 1st intercostal nerve. The branching pattern of the left brachial plexus was normal.



[Table/Fig-1]: MCNAx – Medial cutaneous nerve of axilla, MCNA- Medial cutaneous nerve of arm, MCNFA- Medial cutaneous nerve of forearm, ICBN- Inter-costo-brachial nerve

DISCUSSION

Normal and variant branching pattern of the brachial plexus can be explained on the basis of the embryological development of its roots, divisions and cords [6]. It should be emphasized that the formation or branching pattern of brachial plexus are significantly influenced by their developmental relationship with axillary artery [7]. The development of brachial plexus starts by 34th to 35th day of intrauterine life and definitive adult pattern can be observed by 46th to 48th day of intrauterine life [8]. The expression of chemoattractants and chemorepulsants regulate the guidance of the developing axons in a highly coordinated site-specific fashion; any alterations in signaling between mesenchymal cells and neuronal growth cones can lead to significant variations [9]. Two principal theories have emerged concerning the directional growth of nerve fibers – the neurotropism or chemotropism hypothesis of Ramon Y Cajal [10] and the principle of contact-guidance of Weiss [11]. The salient feature of chemotropism is that axonal growth cones act as sensors to concentration gradients of molecules in the environment and grow up the gradient towards the source, i.e. the target. However, contact guidance mechanisms operate in parallel with neurotropism [11]. Adhesion to the structures with which the growth cone contacts also plays a role. A group of cell surface receptors viz. neural cell adhesion molecule (N-CAM) and L1 and the Cadherins act as transcription factors which recognize and bind to components of the extracellular matrix. Thus, both cell-cell and cell-matrix interactions may be involved in axonal pathfinding [12].

The variant branch of the medial cord of brachial plexus encountered in the present investigation is a rare anatomical entity. It can be justifiably designated as the medial cutaneous nerve of the axilla (MCNAx) (root value- C8, 1) in the view of its distribution to the upper part of the medial wall of axilla. The uniqueness of the present study lies in the fact that medial cord of brachial plexus displayed six branches, three of which originated from a common trunk. We as anatomists also wish to caution that injury to the common trunk arising from the medial cord would probably lead to impairment of sensations in the medial part of arm, forearm as well as the medial wall of axilla. The occurrence of MCNAx, though unique, may be explained on the basis of extension and overlap of the adjacent dermatomal areas. Normally the upper part of the medial wall of axilla is supplied by the lateral cutaneous branch of the ventral ramus of T1 spinal nerve. The dermatomes C5 to C8 are restricted to the upper limb. In the present case, the C8 dermatome has extended on to the medial wall of axilla and is overlapping the T1 dermatome. There is a communication between the intercostobrachial nerve and the medial cord of brachial plexus in 36% cases [10]. A communication between the intercostobrachial nerve and medial cutaneous nerve of the arm has been documented in 18 % of dissections of the axilla [13]. Dermatome rotation flaps of the medial wall of the axilla have recently been used to improve cosmetic results in breast cancer patients and in hydradenitis suppurativa [14, 15]. The knowledge of these communications is essential for a surgeon operating in the region of axilla to prevent damage to these nerves [13].

CONCLUSION

Precise knowledge of the normal and variant branching pattern of brachial plexus is extremely essential for surgeons operating in the region of upper limb and axilla to avoid damage to these nerves. The anatomical details of the medial cutaneous nerve of axilla described in the present study should prove to be useful for surgeons and anaesthetists in their clinical practice.

REFERENCES

- [1] Brunelli G, Brunelli F. Brachial plexus injuries. In: Lamb DW, Hooper G, Kuczynski K, eds. *The Practice of Hand Surgery*. 2nd Ed., Boston, *Blackwell Scientific Publications*. 1989; 218–27.
- [2] Cooke J, Cooke D, Parsons C. The anatomy and pathology of the brachial plexus as demonstrated by computed tomography. *Clin. Radiol*. 1988; 39: 595–601.
- [3] Edwards LF. *Concise Anatomy*. 2nd Ed., New York, McGraw-Hill. 1956; 157–65.
- [4] Gacek RR. Neck dissection injury of a brachial plexus anatomical variant. *Arch. Otolaryngol. Head Neck Surg*. 1990; 116: 356–58.
- [5] Lord, J. W., L. M. Rosati 1971 Thoracic-outlet syndromes. *Clinical Symposia-Geigy*, 23: 1-32.

- [6] Miller RA. Comparative studies upon the morphology and distribution of brachial plexus. *Am J Anat.* 1934; 54: 143–75.
- [7] Miller RA. Observations upon the arrangement of axillary artery and brachial plexus. *Am J Anat.* 1939; 64: 143–63.
- [8] Moore KL, Persaud TVN. The Developing Human. *Clinically Oriented Embryology*. 7th Ed., Philadelphia, Saunders. 2004; 409–23.
- [9] Sannes DH, Reh TA, Harris WA. Development of the Nervous System. New York, *Academic Press*. 2000; 189–97.
- [10] Ramon y, Cajal S. Accion neurotropica de los epitelios. Algunos detalles sobre el mecanismo genetico de las ramificaciones nerviosas intraepiteliales sensitivas y sensoriales. *Trab Lab Invest Biol.* 1919; 17: 65-68.
- [11] Weiss P. Nerve patterns: The mechanics of nerve growth. *Growth (suppl 5)* 1941; 163-203.
- [12] Williams PL, Bannister LH, Berry MM et al. Gray's Anatomy. In: Embryology and development. 38th ed. *London Churchill Livingstone*. 1999; p.231-32.
- [13] O'Rourke MG, Tang TS, Allison SI, Wood W. The anatomy of the extrathoracic intercostobrachial nerve. *Aust N Z J Surg.* 1999 Dec; 69(12): 860-64.
- [14] Kim J, Yoo J, Lee J, Chang E, Suh K. Oncoplastic reconstruction with superior based lateral breast rotation flap after lower quadrant tumor resection. *J Breast Cancer.* 2012 Sep;15(3):350-5.
- [15] Teo WL, Ong YS, Tan BK. Radical surgical excision and use of lateral thoracic flap for intractable axillary hidradenitis suppurativa. *Arch Plast Surg.* 2012 Nov; 39(6):663-66.

AUTHOR(S):

1. Dr. Avinash Thakur
2. Dr. Ashutosh Anshu
3. Dr. Vandana Mehta
4. Dr. Rajesh Kumar Suri
5. Dr. Gayatri Rath

PARTICULARS OF CONTRIBUTORS:

1. Assistant Professor, Department of Anatomy, Vardhman Mahavir Medical College & Safdarjung Hospital, New Delhi- 110029, India.
2. Assistant Professor, Department of Anatomy, Vardhman Mahavir Medical College & Safdarjung Hospital, New Delhi- 110029, India.
3. Professor, Department of Anatomy, Vardhman Mahavir Medical College & Safdarjung Hospital, New Delhi- 110029, India.

4. Director Professor, Department of Anatomy, Vardhman Mahavir Medical College & Safdarjung Hospital, New Delhi- 110029, India.
5. Director Professor, Department of Anatomy, Vardhman Mahavir Medical College & Safdarjung Hospital, New Delhi- 110029, India.

NAME, ADDRESS, E-MAIL ID OF THE CORRESPONDING AUTHOR:

Dr. Avinash Thakur,
B-2/197, Sector-17, Rohini, Delhi-110089, India
Phone: 09310203126
E-mail: thakuravns@gmail.com

FINANCIAL OR OTHER COMPETING INTERESTS:

None.

Date of Submission: **Apr 25, 2013**
Date of Peer Review: **Aug 22, 2013**
Date of Acceptance: **Aug 24, 2013**
Date of Publishing: **Aug 30, 2013**