

Anatomical Variations of Paranasal Sinuses on Coronal CT-Scan in Subjects with Complaints Pertaining to PNS

RAJENDRA KUMAR NARASIPUR LINGAIAH, NANJARAJ CHAKENAHALLI PUTTARAJ,
HARISH ARABAGAPTE CHIKKASWAMY, PRADEEP KUMAR CHANDANUR NAGARAJAIAH,
SANJAY PURUSHOTHAMA, VIJAY PRAKASH, PRIYANKA BOOMA, MOHAMMED ISMAIL

ABSTRACT

Introduction: In the era of Functional Endoscopic Sinus Surgery, precise knowledge of the anatomy and variations of paranasal sinus is essential for the surgeon. Computed tomography provides accurate evictions of the anatomy, the anatomical variants and the extent of the disease in and around the paranasal sinuses.

Aim: To evaluate the anatomical variations of paranasal sinuses using direct coronal CT-scan and to assess the frequency of their occurrence.

Materials and Methods: Over a period of 18 months, 100 consecutive patients referred for CT-scan of PNS region to Department of Radiodiagnosis, MMC&RI (KR Hospital) were evaluated for the presence of normal variants of the paranasal region. Unenhanced CT of the PNS was performed for these patients in the coronal plane, complemented by axial views in selected cases.

Results: Deviated nasal septum was the most common variation in 62(62%) followed by sphenoid sinus septations in 49(49%). Other variations found were middle concha bullosa in 43 (43%) patients, paradoxical middle turbinate in 14 (14%), horizontal uncinat process in 43 (43%), over pneumatized ethmoidal bulla or giant bulla 35 (35%), frontal sinus septations in 31%. Superior concha bullosa in 20 (20%), prominent Agger nasi cells in 26 (26 %), Haller cells in 11 (11%), Onodi cells in 6 (6%), maxillary sinus septae in 12 (12%) and pneumatization of uncinat process in 5 (5%) patients.

Conclusion: Anatomical variations of PNS are quite common. These variations must be identified by the radiologist in preoperative CT evaluation to reduce the risk of intraoperative complications. CT provides a virtual road map to the surgeon and helps improve success of management strategies.

Keywords: Anatomic variants, Functional endoscopic sinus surgery, Intraoperative complications, Sinusitis

INTRODUCTION

Paranasal sinuses (PNS) are the air containing spaces in skull. The paranasal sinuses are the maxillary, ethmoid, frontal and sphenoid sinuses. They lighten the skull, perform the function of humidification of air and provide resonance to voice.

For clinician, precise knowledge of the anatomy of the paranasal sinuses is essential [1]. In the era of Functional Endoscopic Sinus Surgery (FESS), the surgeon requires accurate depiction of the anatomy, variations and extent of pathology preoperatively to avoid intraoperative complications. Various imaging modalities are available for the evaluation of the paranasal sinuses. Conventional radiography provides useful information in the diseases of maxillary and frontal sinuses. But it has limited role in the evaluation of nasal cavity, ethmoid and sphenoid sinuses. The osteo meatal complexes are not delineated by conventional radiography.

Computed tomography provides detailed picture of the anatomy, the anatomical variants and the extent of the disease in and around the paranasal sinuses. Optimal information about the adjacent bones, soft tissues is available with CT making it the imaging modality of choice for assessing PNS.

Along with the axial sections, direct coronal scanning and sagittal reconstructions provide accurate delineation of the micro anatomic locales and disease in the PNS. Coronal CT is the investigation of choice for the detailed evaluation of the osteomeatal complexes and the recesses of the PNS.

CT provides a preoperative road map for functional endoscopic sinus surgery. A combination of CT and diagnostic endoscopy has become the corner stone in the management of paranasal sinus diseases.

Due to its multiplanar capability and excellent soft tissue

resolution, MRI is used as an important modality in the evaluation of the soft tissue pathologies and tumors of the PNS. The main limitation of MRI is its inability to display the skeletal anatomy as compared to CT. Thus, CT is currently used as a method of choice in the evaluation of the paranasal sinuses and adjacent structures.

MATERIALS AND METHODS

This prospective study was performed in the Department of Radiodiagnosis, Mysore Medical College and Research Institute (KR Hospital) Mysore. Total 100 patients who were referred from ENT OPD and wards from December 2013- July 2015 (1/12/2013 to 31/7/2015) with complaints pertaining to PNS were included in the study. Patients with facial trauma, previous sinonasal surgery and paranasal sinus neoplasms were excluded.

The study was performed with the approval of our institutional review board. Written informed consent was taken from every patient.

Patients were subjected to Coronal CT-scans of PNS using GE SYSTEMS-Hi Speed Dual-Slice CT. For CT examination patient was positioned in prone position with neck extended and angulation was perpendicular to hard palate. Imaging was done from posterior margin of sphenoid sinus to anterior margin of frontal sinus. Thickness was 5mm slices with 3mm retro reconstruction. Exposure parameters were 120 kVp, 130 mAs, 1.5 seconds scan time. Bone window width was 4000 HU and window level was 500HU. Soft tissue window width was 90 HU and window level was 40HU.

The images were reviewed using bone and soft tissue windows and the details were analyzed:

1. Septum Deviation
2. Agger nasi pneumatized
3. Bulla Ethmoidalis
4. Uncinate process
5. Middle turbinate: pneumatisation
6. Maxillary sinus septation
7. Pneumatized superior turbinate
8. Supraorbital cell
9. Haller cell
10. Onodi cell
11. Frontal sinus
12. Cribriform Plate
13. Extramural sphenoid pneumatization
14. Other findings: Inflammatory sinus disease acute, chronic or allergic. If present, in which sinus?

STATISTICAL ANALYSIS

SPSS for windows (version 20.0) was employed for statistical analysis. Results were cross tabulated. Frequencies,

descriptive statistics were the statistical methods used. Level of significance of findings was assessed by Chi-square test.

RESULTS

On the whole there were 49 male and 51 female patients [Table/Fig-1] depicts the distribution of sample by age and sex. The mean age of the male sample was found to be 30.17 +11.05 years, whereas the mean age of the female samples was found to be 29.51+13.55 years. Further, the mean age of the total sample irrespective of the sex was 29.91+12.01 years. We find most of the patients in the age groups of <20, 21-30, and 31-40 years and very few of them in higher age groups. This was found to be statistically significant as the observed chi-square value of 46.52 was found to be highly significant at.001 level. Gender-wise no statistical difference was observed. Chi-square test value of 3.24 was found to be non-significant (p=0.072).

In our study 62% of patients showed deviated nasal septum and also showed slight predominance to the left side (29%) as compared to right side (23%). On statistical basis p values were also significant (p ≤ 0.001) [Table/Fig-2,3].

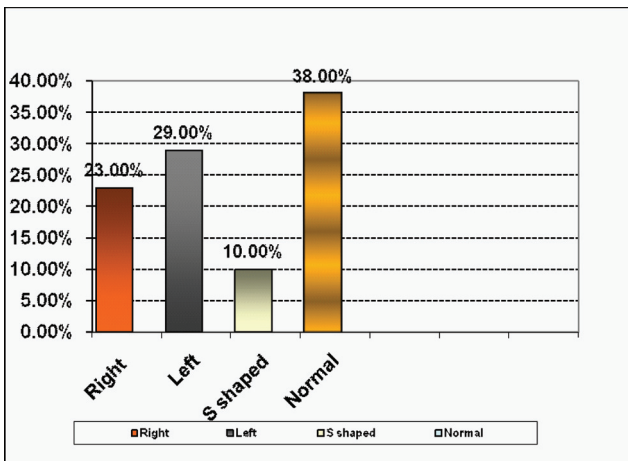
As far as the special cells are considered in the paranasal sinuses the variation of occurrence of these special cells were found to be significant as their p values are below 0.05. The most common was Agger Nasi cells (26%), followed by Haller

Age groups (in years)	Sex		Total
	Male	Female	
≤ 20	17 (34.7%)	10 (19.6%)	27 (27%)
21-30	12 (24.5%)	21 (41.2%)	33 (33%)
31-40	11 (22.4%)	11 (21.6%)	22 (22%)
41-50	6 (12.2%)	5 (9.8%)	11 (11%)
51-60	3 (6.1%)	2 (3.9%)	5 (5%)
61 and above	0 (0%)	2 (3.9%)	2 (2%)
Total	49 (100%)	51 (100%)	100 (100%)

[Table/Fig-1]: Distribution of the sample by age and sex. $CC_{(age\ and\ sex)} = .13$; $p = .446$; $Chi-square_{(age\ groups)} = 46.52$; $p \leq .001$; $Chi-square_{(sex)} = 3.24$; $p = .072$

Types	No. of Patients	Percentage
I	37	37%
II	13	13%
III	9	9%
IV	10	10%
V	20	20%
VI	6	6%
VII	5	5%
Total	100	100%

[Table/Fig-2]: Types of deviated nasal septum.

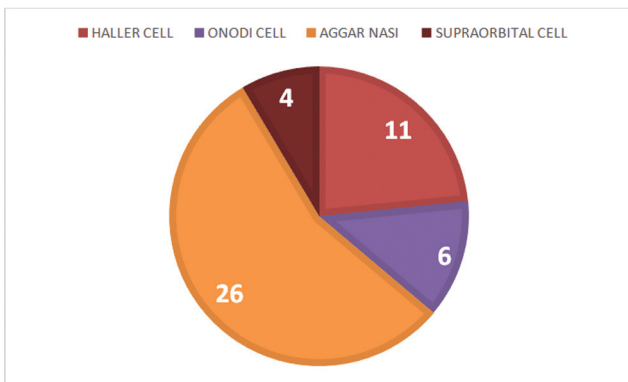


[Table/Fig-3]: Frequency of occurrence of DNS.

cell (11%) and Onodi cell (4%) [Table/Fig-4].

Among the patients taken for the study the orientation of the uncinate process varies from horizontal to vertical. The p-value which was calculated to be 0.162 was found to be non significant [Table/Fig-5].

In the study the variations in the middle turbinate are of paradoxical and typical type. The p value was 0.001 for variations in middle turbinate which is statistically highly significant [Table/Fig-6]



[Table/Fig-4]: Frequency of occurrence of special cells.

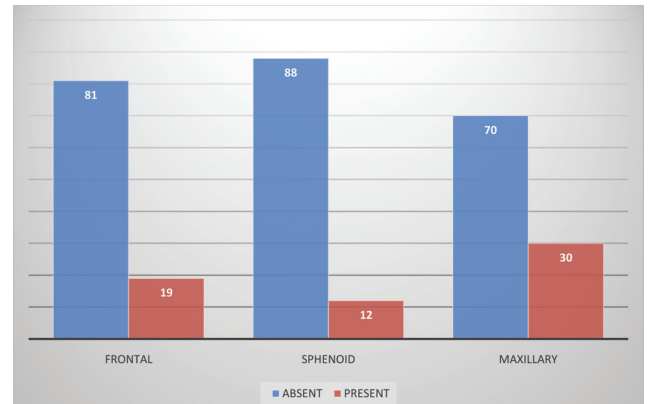
	Frequency	Percentage (%)	Chi square	p-value
Horizontal	43	43.0	1.96	0.162
Vertical	57	57.0		
Total	100	100.0		

[Table/Fig-5]: Orientation of uncinate process.

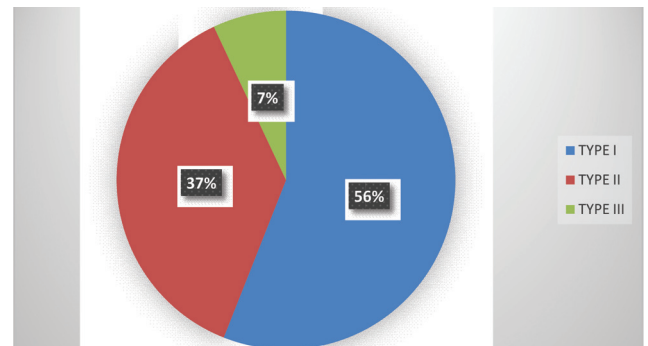
	Frequency	Percentage (%)	Chi square	p-value
Paradoxical	14	14.0	126.9	0.001
Typical	86	86.0		
Total	100	100.0		

[Table/Fig-6]: Middle turbinate variations.

Septations were most common in Sphenoid sinus (12%) [Table/Fig-7]. In the cribriform plate Keros type I (56%) was most commonest [Table/Fig-8].



[Table/Fig-7]: Occurrence of septations in various paranasal sinuses.



[Table/Fig-8]: Cribriform plate type variation.

DISCUSSION

Nasal cavity and para nasal sinuses together form a single anatomical and functional unit. This region is subject to a large variety of lesions. Congenital anomalies and normal anatomical variations in this region are a rule rather than exception. Conventional X-rays don't provide adequate information because of structural superimposition. There has been tremendous advances in the surgical treatment of sinusitis in recent years, particularly in Functional Endonasal Endoscopic Surgery (FESS), which requires the clinician to have a precise knowledge of nasal sinus anatomy and anatomical variants, many of which are detectable only by the use of CT.

In our study, the anatomic variations have been described as determined by coronal CT in a series of 100 cases.

Age and Sex Determination

Among 100 patients selected for the study of variations in the paranasal sinus 49 (49%) were males and 51 (51%) females. Majority of the subjects, 12 males and 21 females, total 33 (33%) patients were in the age group of 21– 30 years. Gender-wise, no statistical difference was observed.

Deviated Nasal Septum

In a study of 110 subjects by Perez-Pinas J Sabate et al., [1], 80 subjects showed DNS. Most were non traumatic deviations of the septum (64 cases, 72%); the numbers of left and rightward deviations were similar, with a slight predominance of the former. According to John Earwaker [2] deviated nasal septum (55%) is the most common variation, in his study there is slight predominance towards right side. In study by Talaiepour AR et al., [3], they found deviated nasal septum in 63% (28.0% deviated to the right, 31.5% to the left and bilateral deviation in 3.5%).

In our study 62% of patients showed deviated nasal septum and also showed slight predominance to the left side (29%) as compared to right side (23%). On statistical basis p values were also significant ($p \leq 0.001$).

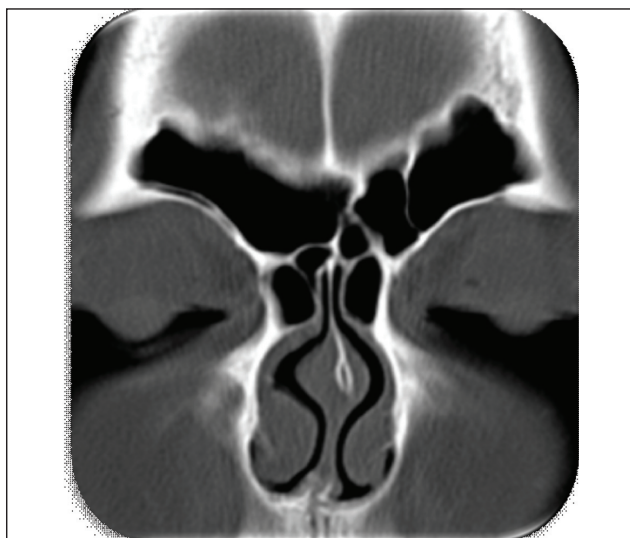
Occurrence of Special Cells

In the literature, the presence of Aggernasi cells varies from 10% to 98.5% is described in [Table/Fig-9]. In the study by Talaiepour AR et al., [3] study Agger nasi was seen in 56.7% of cases, with 17.5% on the right, 7.7% left and 31.5% bilateral. In our study the occurrence of Agger nasi cells [Table/Fig-10] falls within the range of various studies i.e. (26%).

According To John Earwaker [2], occurrence of Onodi cell is

Studies	Agger Nasi cell
Talaiepour et al., [3]	56.7%
Davis et al., [4]	65%
Van Alyea [5]	89%
KhonKaen University [7]	95%
Zinreich [6]	98.5%

[Table/Fig-9]: Prevalence of Agger nasi cells in various studies.



[Table/Fig-10]: Bilateral Agger nasi.

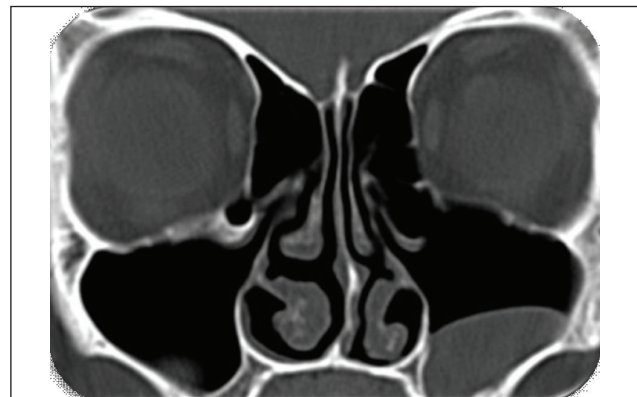
191 out of 800 patients studied i.e. 24%.

According to Talaiepour AR et al., [3], Onodi cell appeared on 7% of the scans with 2.8% on the right, 0.7% left and 3.5% located bilaterally.

In study by Dua K et al., [7], occurrence of Onodi cell is 6% out of 50 patients studied. In our study the occurrence of Onodi cells is 6%.

Talaiepour AR et al., [3], study showed presence of Haller cells in 3.5% of all subjects with 1.4% on the left and 2.1% bilateral; none were observed on the right side. The occurrence of Haller cell is variable according to various studies.

Dua K, et al., [7], study showed occurrence of Haller cell is 16% while Jack M Gwaltney et al., [8], showed the occurrence of Haller cells is 45%. According to Mohannad A Al Qudah [9], Haller cell was noted in 20%. In our study occurrence of Haller cells [Table/Fig-11] is 11%.



[Table/Fig-11]: Haller cell.

Since, the optic nerve is in close relation with Onodi cells when present, accurate delineation of optic nerve is important in preoperative planning. The presence of Onodi cells is the most important factor limiting posterior extent of endoscopic clearance.

In our study the p values of various special cells was found to be statistically highly significant as they fall below $p < 0.05$.

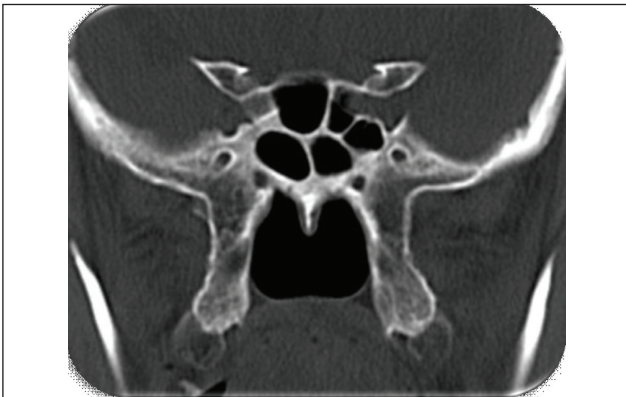
Occurrence of Septation in Various Sinuses

According to John Earwaker [2], maxillary sinus showed septations in about 19 cases out of 800 patients studied. According to Abdullah BJ et al., [10], out of 70 patients studied 68.9% showed septations in the sphenoid sinus.

In our study frontal sinus showed septations in about 31%. Maxillary sinus showed septations in about 19%. Sphenoid sinus showed septations [Table/Fig-12] in about 49%.

Hypoplasticity of Various Paranasal Sinuses

In the study by Binali Çakur et al., [11], showed that 0.56% of cases showed hypoplastic sphenoid sinus. Identification



[Table/Fig-12]: Sphenoid sinus septa.

of this variation is of paramount importance in preoperative evaluation of trans-sphenoidal hypophysectomy.

In our study a total of 3% of cases comprised to have hypoplastic sphenoid sinus.

Maxillary sinus hypoplasia is rare but can be mistaken for chronic sinusitis. Zinreich SJ [12] found the prevalence of unilateral hypoplastic maxillary sinus to be 10.4%. In our study Maxillary sinus hypoplasia showed 2% bilaterally.

Maxillary sinus hypoplasia may predispose to orbital penetration during endoscopic sinus surgery; therefore the surgeon must be informed of this abnormality preoperatively to avoid injury to globe or other orbital structures [12].

In our study frontal sinus hypoplasia was noted in 17% in which 3% were bilateral.

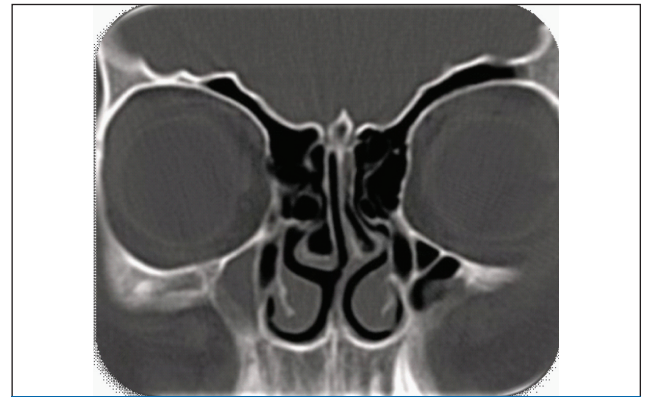
Frequency of Variations of Middle Turbinate

Literature reports a wide variation in the incidence of middle turbinate pneumatization [Table/Fig-13]. Concha bullosa was found in 35% cases in the study by Talaiepour AR et al., [3]. Of these, 11.9% were on the right, 11.2% left and 11.9% occurred as a bilateral anatomic variation. According to John Earwaker [2] 443 patients showed concha bullosa out of 800 patients studied.

In our study 43% of the cases showed concha bullosa [Table/Fig-14,15] out of which bilateral is the maximum of about 41% followed by right side of about 32% and least is on the left side

Studies	Prevalence
Joe JK et al., [13]	15%
Liu X et al., [14]	34.85%
Basic N et al., [15]	42%
Lothrop et al., [16]	9%
Davis et al., [4]	8%
Shaeffer et al., [17]	11%

[Table/Fig-13]: Prevalence of pneumatized middle turbinate in various studies.



[Table/Fig-14]: Maxillary sinus septa with right concha bullosa and DNS to left.

	Frequency	Percent (%)	Chi square	p-value
Absent	57	57.0	55.6	0.001
Bilateral	18	18.0		
Left	11	11.0		
Right	14	14.0		
Total	100	100.0		

[Table/Fig-15]: Concha bullosa variations.

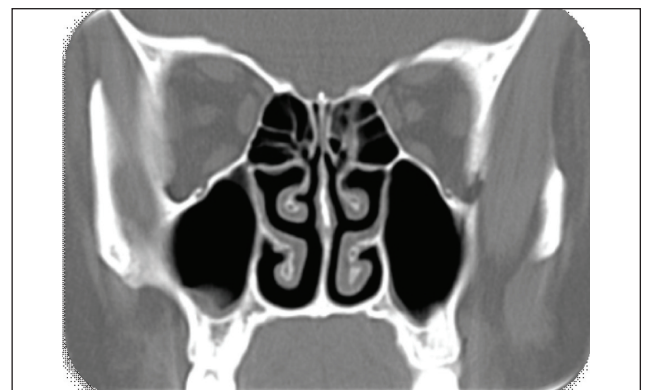of about 25%.

Presence of a concha bullosa does not suggest a pathological finding. However, in the setting of chronic sinus disease, resection of the concha bullosa should be considered to improve paranasal sinus access. Further, the concha bullosa interior may be affected by disease in other sinuses [17].

Paradoxically Bent Middle Turbinate

A distorted middle turbinate which faces towards the meatus is itself not pathologic but can contribute to severe narrowing of the middle meatus if other mucosal derangements are present.

We found paradoxical curvature of middle turbinate [Table/Fig-16] in 14%. Prevalence of paradoxical middle turbinate is



[Table/Fig-16]: Paradoxical middle turbinate on right side with type I cribriform plate.

slightly higher in our study compared to other studies [Table/Fig-17].

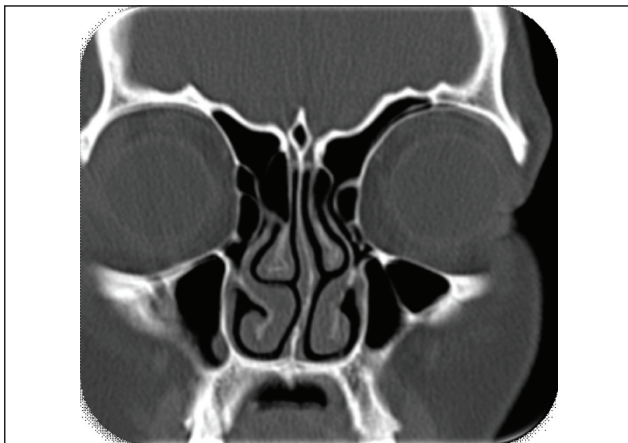
Author	Prevalence
Calhoun [18]	7.9%
Lusk et al., [19]	8.5%

[Table/Fig-17]: Prevalence of paradoxical middle turbinate in various studies.

Orientation of the Uncinate Process

Earwaker [2] observed horizontal orientation of the uncinat process, unilaterally or bilaterally in 19% of cases, the variant was associated with an enlarged ethmoidal bulla and, in some cases, with contralateral septal deviation. Vertical orientation of the process which appeared enlarged or deformed was observed in 32% of patients.

In our study 43% of cases showed horizontal orientation [Table/Fig-18] of the uncinat process (with 82% of the cases associated with enlarged ethmoidal bulla) and 57% cases showed vertical orientation of the uncinat process (with 8.7% of the cases associated with enlarged ethmoidal bulla).

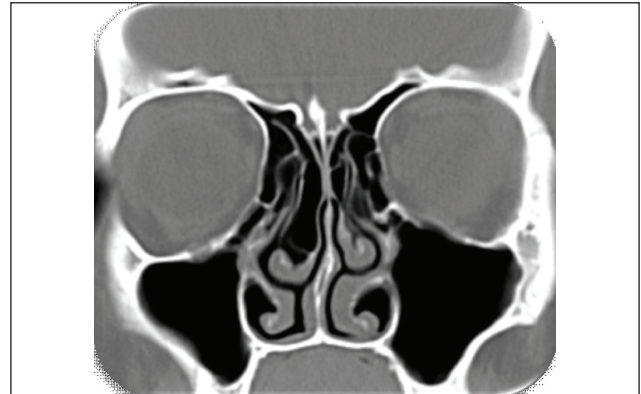

[Table/Fig-18]: Uncinat process vertical on right and horizontal on left side with crista galli pneumatization.

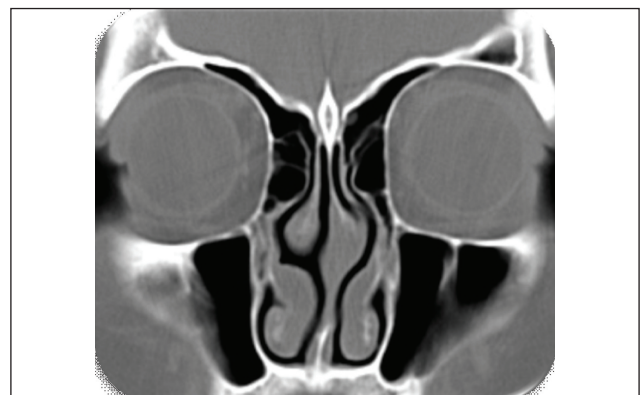The frontal recess drainage is determined by the superior attachment of uncinat process. Infundibular disease will be seen if uncinat process is attached to the skull base or middle turbinate as the frontal recess opens into the ethmoidal infundibulum. Infundibular disease will be spared when the superior attachment is to the lamina papyracea, the frontal sinus will open into the middle meatus directly. During surgery, it is important to clear this attachment to gain access to frontal recess. Infundibulum will be narrowed in lateral deflections of uncinat process, while a more medial deflection can narrow and obstruct the middle meatus. Care needs to be taken while performing uncinectomy to prevent orbital injury because of the reduced distance between the lateralized uncinat process and lamina papyracea [13].

Cribriform Plate

Soraia Ale Souza et al., [20] study showed Keros type II [Table/Fig-19] as the most common variant (73.3%) followed by type I in 26.3% and type III [Table/Fig-20] in 0.5% of cases. However, in our study Type I is commonest. The type of cribriform plate is important in predicting the intra operative complications during FESS.



[Table/Fig-19]: Type II cribriform plate.



[Table/Fig-20]: Type III cribriform plate.

LIMITATIONS

Since, this is a non-enhanced contrast CT study, vascular structures like Internal carotid artery could not be optimally assessed for its protrusion or dehiscence in sphenoid sinus.

CONCLUSION

Direct coronal CT is the imaging modality of choice for the evaluation of the anatomical variations in paranasal sinuses. Coronal CT-scan provides more detailed information of the posterior sinus variations. In our study DNS to the left is the most common variation. Among the special cells, Agger nasi cell is the most common type. Septations in paranasal sinuses is most common in sphenoid sinus. Vertical orientation of uncinat process is the most common variety. Type I variety of the cribriform plate is the most common type. Thin sections provide more detailed variations on coronal CT-scan. The

frequency of occurrence of anatomical variations and their influence on causing sinus disease can be assessed.

REFERENCES

- [1] Perez-Pinas I, Sabate J, Carmona A, Catalina HCJ, Jimenez CJ. Anatomical variations in the human paranasal sinus region studied by CT. *J Anat.* 2000;197(2):221-27.
- [2] Earwaker J. Anatomic variants in sinonasal CT. *Radiographics.* 1993;13(2):381-415.
- [3] Talaiepour AR, Sazgar AA, Bagheri A. Anatomic variations of the paranasal sinuses on CT scan images. *Journal of Dentistry, Tehran University of Medical Sciences.* 2005; 2(4):142-46.
- [4] Davis WE, Templer J, Parsons DS. Anatomy of the paranasal sinuses. *Otolaryngol Clin North Am.* 1996;29(1):57-74.
- [5] Van Alyea OE. Sphenoid sinus. Anatomic study with consideration of the clinical significance of the characteristics of the sphenoid sinus. *Arch Otolaryngol.* 1941;34:225-53.
- [6] Kennedy DW, Zinreich SJ. The functional endoscopic approach to inflammatory sinus disease: current perspectives and technique modifications. *Am J Rhinol.* 1988;2:89-93.
- [7] Dua K, Chopra H, Munjal M. CT-scan variations in chronic sinusitis. *IJRI.* 2005;15(3):315-20.
- [8] Gwaltney JM Jr, Phillips CD, Miller RD, Riker DK. Diseases of the Sinuses. *N Engl J Med.* 1994;330(1):25-30.
- [9] Al-Qudah MA. Anatomical variations in sinonasal region: A computer tomography (CT) study. *J Med Chem.* 2010;44:290-97.
- [10] Abdullah BJ, Arasaratnam S, Kumar G, Gopala K. The sphenoid sinuses: computed tomography assessment of septation, relationship to the internal carotid arteries, and sidewall thickness in the Malaysian population. *J HK Coll Radiol.* 2001;4:185-88.
- [11] Cakur B, Sümbüllü MA, Yılmaz AB. A retrospective analysis of sphenoid sinus hypoplasia and agenesis using dental volumetric CT in Turkish individuals. *Diagn Interv Radiol.* 2011;17(3):205-08.
- [12] Zinreich SJ. Paranasal sinus imaging. *Otolaryngol head neck surg.* 1990;103(5):868-69.
- [13] Joe JK, Ho SY, Yanagisawa E. Documentation of variations in sinonasal anatomy by intra-operative nasal endoscopy. *Laryngoscope.* 2000;110(2-1):229-35.
- [14] Liu X, Zhang G, Xu G. Anatomic variations of the ostiomeatal complex and their correlation with chronic sinusitis: CT evaluation. *ZhonghuaEr Bi Yan HouKeZaZhi.* 1999;34(3):143-46.
- [15] Basic N, Basic V, Jukic T, Basic M, Jelic M, Hat J. Computed tomographic imaging to determine the frequency of anatomical variations in pneumatization of the ethmoid bone. *Eur Arch Otorhinolaryngol.* 1999;256(2):69-71.
- [16] Lothrop HA. The anatomy of the inferior ethmoidal turbinate bone with particular reference to cell formation. Surgical importance of such ethmoid cell. *Ann Surgery.* 1903; 38:233-55.
- [17] Shaeffer SD. An anatomic approach to endoscopic intranasal ethmoidectomy. *Laryngoscope.* 1998;108(11-1):1628-34.
- [18] Calhoun KH, Waggenspack GA, Simpson CB, Hokanson JA, Bailey BJ. CT evaluation of the paranasal sinuses in symptomatic and asymptomatic populations. *Otolaryngol Head Neck Surg.* 1991;104(4):480-83.
- [19] Lusk RP, McAlister B, Fouley A. Anatomic variation in pediatric chronic sinusitis: A CT study. *Otolaryngology Clin North Am.* 1996;29:75-91.
- [20] Souza SA et al. Computed tomography assessment of the ethmoid roof: a relevant region at risk in endoscopic sinus surgery. 2008;41(3):143-47.

AUTHOR(S):

1. Dr. Rajendra Kumar Narasipur Lingaiah
2. Dr. Nanjaraj Chakenahalli Puttaraj
3. Dr. Harish Arabagapte Chikkaswamy
4. Dr. Pradeep Kumar Chandanur Nagarajaiah
5. Dr. Sanjay Purushothama
6. Dr. Vijay Prakash
7. Dr. Priyanka Booma
8. Dr. Mohammed Ismail

PARTICULARS OF CONTRIBUTORS:

1. Associate Professor, Department of Radiodiagnosis, Mysore Medical College and Research Institute, Mysore, India.
2. Professor and HOD, Department of Radiodiagnosis, Mysore Medical College and Research Institute, Mysore, India.
3. Junior Resident, Department of Radiodiagnosis, Mysore Medical College and Research Institute, Mysore, India.
4. Assistant Professor, Department of Radiodiagnosis, Mysore Medical College and Research Institute, Mysore, India.

5. Senior Resident, Department of Radiodiagnosis, Mysore Medical College and Research Institute, Mysore, India.
6. Junior Resident, Department of Radiodiagnosis, Mysore Medical College and Research Institute, Mysore, India.
7. Junior Resident, Department of Radiodiagnosis, Mysore Medical College and Research Institute, Mysore, India.
8. Junior Resident, Department of Radiodiagnosis, Mysore Medical College and Research Institute, Mysore, India.

NAME, ADDRESS, E-MAIL ID OF THE CORRESPONDING AUTHOR:

Dr. Rajendra Kumar Narasipur Lingaiah,
Associate Professor, Department of Radiodiagnosis,
Mysore Medical College and Research Institute,
Irwin Road, Mysore-570001, Karnataka, India.
E-mail: drnrk999@gmail.com

FINANCIAL OR OTHER COMPETING INTERESTS:

None.

Date of Online Ahead of Print: Sep 01, 2016