

# Surgical Management of a Large Carotid Body Tumour with 8 Years Follow-Up

ANSHUMAN KUMAR, APALA BADUNI

## ABSTRACT

The most frequently present paraganglioma of the head and neck region is Carotid Body Tumour (CBT) which originates at the bifurcation of the common carotid artery. Surgical treatment although is recommended but due to its complicated anatomical location, i.e., its nearness to

the cranial nerves and the arterial system it is difficult to operate. We hereby present a case report of a successful surgical resection of a Shambling Type III CBT with 8 years follow-up. As per our knowledge this is one of the largest CBT reported in the literature.

**Keywords:** Common carotid artery, Internal carotid artery, Paraganglioma, Shamblin type III

## CASE REPORT

A 52-year-old female patient from Afghanistan came to Dharamshila Hospital and Research Centre with the complaint of respiratory distress since 2 days and neck swelling on the left side along with pain in the left ear since 6 months.

No relevant medical history was present. Personal history revealed that the patient was a non-smoker and a non drinker. No family history of cancer, diabetes and heart disease was reported.

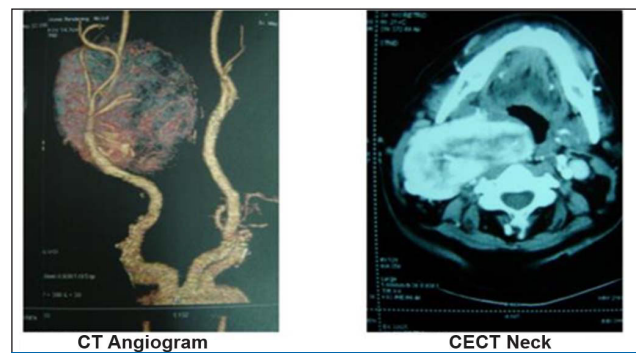
On inspection the lesion was present on the left lateral neck, it was irregular in shape measuring approximately 8 x 7 cm with smooth surface and irregular margins. It extended from the mastoid process to below the cricoid cartilage. Anterior boundary was approximately 1.5 inches from the midline and posteriorly it extended till the lateral border of sternocleidomastoid. Inspectory findings were confirmed by palpation. The swelling was soft in consistency, non-pulsatile, mobility was present horizontally however absent in the vertical axis. Bruit was present on auscultation. Differential diagnosis like neurogenic tumour, neuroblastoma, paraganglioma, and aneurysm were considered.

Fine needle aspiration was done from the swelling behind right angle of the jaw. The examination of the smear revealed that a vague follicular pattern and atypical cells with abundant cytoplasm with marked anisokaryosis and occasional presence of intranuclear inclusions. The features were suggestive of paraganglioma.

Chest X-ray was normal, direct pharyngolaryngoscopy revealed external compression on right lateral pharyngeal wall,

pyriform fossa and hemilarynx, compromising the laryngeal inlet. No mucosal irregularity was seen. Ultrasonography neck with Doppler showed a large mass in the neck on right splaying the carotid bifurcation. The right internal carotid was surrounded by the mass and the right external carotid appeared to be surrounded at its origin but was free thereafter. MRI neck suggested a large CBT encircling the internal carotid artery and the origin of external carotid artery [Table/Fig-1]. A preoperative diagnosis of CBT was given.

The case was discussed in the tumour board, and the surgery was planned. After obtaining the informed consent, the patient



**[Table/Fig-1]:** CT angiogram and CECT neck showing the CBT.

was admitted and the excision of the tumour was planned under general anaesthesia.

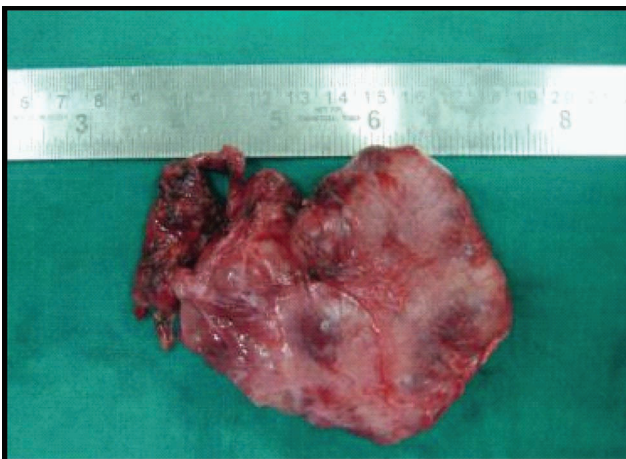During the surgical procedure neck flap was raised at a subplatysmal level. The sternocleidomastoid was dissected and retracted laterally followed by the internal jugular vein which

was also dissected and freed from the tumour. Hypoglossal nerve was dissected and preserved and the common carotid artery was dissected and isolated. The external carotid artery was ligated and cut at origin. Tumour was then dissected from the parapharyngeal wall and was reflected laterally. Internal carotid artery was dissected off the tumour and preserved. The tumour was removed, lavage was done and haemostasis was achieved after which drain was put and closure was achieved. The surgery took 8 hours to complete. A standby was prepared for arterial shunt however it was not required as the result was achieved using a bipolar electrocautery on a beating artery. Even though the size of the tumour was substantial, no intraoperative or postoperative complications were encountered.

The patient had no complications and was discharged in good health with no nerve injury or cerebral ischemia.

The gross specimen measured 7.5x 7.0 x 3.5 cm [Table/Fig-2]. Cut surface was nodular and appeared shaggy at places. With solid white grey surface with focal areas of haemorrhage. Multiple sections were examined and the features were compatible with paraganglioma.

The patient was under regular follow up and even after 8 years of surgery patient was in good condition. CT-scan and MRI shows no evidence of residual or recurrence.



[Table/Fig-2]: Specimen of carotid body tumour.

## DISCUSSION

The most frequently present paraganglioma of the head and neck region is CBT which originates at the bifurcation of the common carotid artery from the glomus cells [1,2]. Although they are usually benign but in 6-12.5% cases malignancy could occur [3].

It is commonly present in people who live in high altitudes as the decreased partial pressure of oxygen there, can stimulate the carotid body which can then increase in size. Hypoxia due to sleep apnoea can also lead to the same [4,5].

Surgical treatment although is recommended but due to its complicated anatomical location i.e., its nearness to the cranial nerves and the arterial system it is difficult to operate, this especially holds true for Shamblin Type III tumours [6]. The risk of both morbidity and mortality increases by 67% in the patients with tumour size larger than 5 cm [7].

Initially, when the CBT is small the clinical symptoms are not obvious. With increase in size various symptoms like hoarseness, vocal cord paralysis, otalgia, dysphasia Horner's syndrome, pulsation, a thrill or a bruit, cerebral ischemia, or carotid sinus syndrome might be present [8].

Shamblin classified CBTs, into three types which are based on the relationship of the mass to the wall of carotid artery.

**Type I** has tumour size less than 5cm, the carotid bifurcation is not widened and surgery can be performed with ease.

**Type II** is attached to the wall with absence of encasement, while.

**Type III** is more than 5cm in size present inside the blood vessel in the encasement of the vessel wall, the bifurcation is also widened. Operating Shamblin Type III has poor outcome due to nerve injuries which can be both permanent or temporary especially involving the hypoglossal, vagus, marginal mandibular branch of facial nerve and the sympathetic chain [9,10].

Researchers have debated whether radiotherapy or surgery should be performed in CBTs, especially the larger ones like Shamblin type III due to the risk of intraoperative bleed but surgery still remains the primary treatment option as fibrosis takes pace post radiotherapy which makes operation hard. Also assessment of the growth tumour will be difficult after radiotherapy especially when it can be potentially malignant. Radiotherapy should be used in inoperable cases [11,12].

## CONCLUSION

As per our knowledge this is one of the largest carotid body tumour reported in the literature. Surgery should be the primary treatment option for CBT but it should be performed with caution with an experienced surgical team.

## REFERENCES

- [1] Ma D, Liu M, Yang H, Ma X, Zhang C. Diagnosis and surgical treatment of carotid body tumour: A report of 18 cases. *J Cardiovasc Dis Res.* 2010;1(3):122-24.
- [2] Dixon JL, Atkins MD, Bohannon WT, Buckley CJ, Lairmore TC. Surgical management of carotid body tumours: a 15-year single institution experience employing an interdisciplinary approach. *Proc (Baylor University Medical Center).* 2016;29(1):16-20.
- [3] Rekha A, Ravi A, Vijayaraghavan KS. Paraganglioma neck - a neuroendocrine tumour revisited. *Int J Angiol.* 2008;17(3):162-65.
- [4] Wani B, Agni N, Rathod V, Bhole A. Rural centre based management of the carotid body tumour. *Indian J Otolaryngol Head Neck Surg.* 2011;63(Suppl 1):107-09.

- [5] Knight TT Jr, Gonzalez JA, Rary JM, Rush DS. Current concept for the surgical management of carotid body tumour. *Am J Surg.* 2006;191:104-10.
- [6] Nagarkar R, Roy S, Akheel M, Palve V, Pandit P, Kulkarni N. Carotid body tumours: series of case report and retrospective analysis: an institutional audit. *Int J Dent Med Spec.* 2015;2(1):24-29.
- [7] Elsharawy MA, Alsaif H, Elsaid A, Kredees A. Management of sizeable carotid body tumour: Case report and review of literature. *Avicenna J Med.* 2013; 3(4):106-08.
- [8] Park SJ, Kim YS, Cho HR, Kwon TW. Huge carotid body paraganglioma. *Journal of the Korean Surgical Society.* 2011;81(4):291-94.
- [9] Lim JY, Kim J, Kim SH, Lee S, Lim YC, Kim JW, et al. Surgical treatment of carotid body paragangliomas: outcomes and complications according to Shamblin classification. *Clin Exp Otorhinolaryg.* 2010;3(2):91-95.
- [10] Luna-Ortiz K, Rascon-Ortiz M, Villavicencio-Valencia V, Granados-Garcia M, Herrera-Gomez A. Carotid body tumours: review of a 20-year experience. *Oral Oncol.* 2005;41(1):56-61.
- [11] Persky MS, Setton A, Niimi Y, Hartman J, Frank D, Berenstein A. Combined endovascular and surgical treatment of head and neck paragangliomase: A team approach. *Head Neck.* 2002;24:423-31.
- [12] Mozafar M, Radpey MR, Tadayon N, Atqiaee K, Lotfollahzadeh S, Sobhiyeh MR, et al. A 10 year experience on surgical management of carotid body tumours. *J Thrita.* 2014;3(1):e11359.

**AUTHOR(S):**

1. Dr. Anshuman Kumar
2. Dr. Apala Baduni

**PARTICULARS OF CONTRIBUTORS:**

1. Director, Department of Surgical Oncology, Dhramshila Cancer Hospital, Delhi, India.
2. Research Fellow, C3 Healthcare, Delhi, India.

**NAME, ADDRESS, E-MAIL ID OF THE CORRESPONDING AUTHOR:**

Dr. Anshuman Kumar,  
C3 Healthcare, 115, Vardhaman Sunrise Plaza,  
Vasundhara Enclave, Delhi-110096, India.  
E-mail: dranshumankumar@gmail.com  
apalabaduni@gmail.com

**FINANCIAL OR OTHER COMPETING INTERESTS:**

None.

Date of Publishing: Jul 01, 2017