

# Comparison of Point of Care Ultrasound and Magnetic Resonance Imaging for the Diagnosis of Necrotising Soft Tissue Infections: A Cross-sectional Study

AMARNATH CHELLATHURAI<sup>1</sup>, THANGALAKSHMI ADAIKALAM<sup>2</sup>, NELLAIAPPAN CHELLIAH<sup>3</sup>, BHARATHI PRIYA RAJU<sup>4</sup>, SATHYAN GNANASIGAMANI<sup>5</sup>, SHYAMALA MURUGESAN<sup>6</sup>



## ABSTRACT

**Introduction:** Necrotising fasciitis requires a high index of clinical suspicion in the early stages since it is difficult to distinguish it from common skin diseases like cellulitis or harmless wound infections. Despite improvements in antibiotic therapy and intensive care, Necrotising Soft Tissue Infections (NSTIs) still have a high mortality rate. Point-of-Care Ultrasound (POCUS) can increase the efficiency and precision of diagnostics. Magnetic Resonance Imaging (MRI) has a higher sensitivity and specificity in diagnosing the infection. However, Computed Tomography (CT) and MRI are not always readily available in clinical practice settings and can have other drawbacks, such as being a time-consuming and expensive method.

**Aim:** To define how POCUS can be used as an initial and primary modality for diagnosis of NSTI.

**Materials and Methods:** The present cross-sectional study was conducted in the Department of Radiodiagnosis, Stanley Medical College, Chennai, Tamil Nadu, India, from April 2021 to March 2022. A total number of 40 patients of any age group and sex, who were suspected to have soft tissue infections were included. After doing a bedside ultrasound in all 40 patients, in 36 MRI was performed. MRI was considered

the gold standard technique in the diagnosis of NSTI. The Ultrasonography (USG) and MRI findings were compared. The imaging findings taken into consideration for predicting NSTI include subcutaneous thickening, subcutaneous fluid collection, muscular oedema, and subcutaneous air pockets. Sensitivity, specificity, Positive Predictive Value (PPV), and Negative Predictive Value (NPV) were calculated.

**Results:** The mean age of study population was 52 years. The incidence in males was 62.5% (25 patients) and in females was 37.5% (15 patients). The lower limb was the most frequently affected site involving the 25 (62.5%) patients. Out of 40 patients, 38 patients had subcutaneous thickening, 28 patients had subcutaneous fluid collection, 20 patients had muscular oedema and 13 patients had subcutaneous air pockets. Out of 13 patients who had subcutaneous air pockets four people had extensive air pockets and the USG findings were obscured in that four cases due to reverberation artifacts caused by air pockets. In the current study, POCUS has a sensitivity of 93.5%, specificity of 80%, PPV of 96%, NPV of 66.67%, and accuracy of 91.67%.

**Conclusion:** According to the observations, the present study concluded that POCUS has a higher sensitivity in diagnosing NSTI.

**Keywords:** Cellulitis, Diabetes complication, Subcutaneous fat

## INTRODUCTION

Necrotising fasciitis is an infection that affects the deep soft tissue structures that progress rapidly and poses a life-threatening risk. Necrotising fasciitis is a polymicrobial infection that affects the extremities, the perineum and genital area, and the abdominal wall [1]. It requires a high index of clinical suspicion in the early stages since it is difficult to distinguish from common skin diseases like cellulitis or harmless wound infections [2]. Delay in making proper diagnosis and surgical exploration leads to high morbidity and even mortality. Clinical diagnosis can be challenging, but imaging studies can be useful in suggesting an early diagnosis [2]. When the suspicion is high, surgical intervention should not be postponed [2]. The most frequently employed diagnostic techniques in patients with suspected necrotising fasciitis are Computed Tomography (CT) and Magnetic Resonance Imaging (MRI). MRI has a higher sensitivity and specificity in diagnosing the infection. However, CT and MRI are not always readily available in clinical practice settings and can have other drawbacks, such as being a time consuming and expensive method [3]. Ultrasonography (USG) is a widely used technique for assessing soft tissue. Point-of-Care Ultrasound (POCUS) has received a lot of attention recently from the medical community as a supplement to clinical assessment [3]. The current study shows

how POCUS can add to the body of knowledge used to diagnose Necrotising Soft Tissue Infection (NSTI) and shows the utility for the decision making process in a disease where an early diagnosis is essential.

## MATERIALS AND METHODS

It was cross-sectional study conducted in the Department of Radiodiagnosis, Stanley Medical College, Chennai, Tamil Nadu, India, from April 2021 to March 2022 after obtaining ethical committee clearance (20201217).

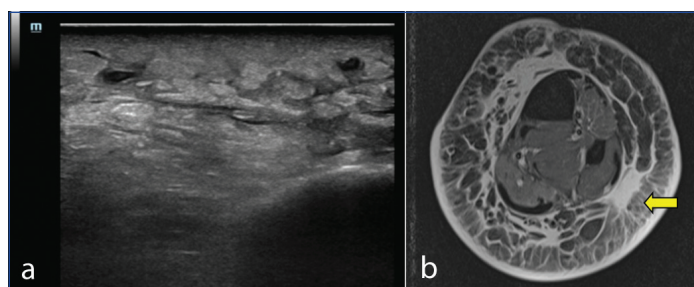
**Inclusion criteria:** A total number of 40 patients of any age group and sex, who had clinical features of pain swelling, redness, and tenderness of the locally affected region and fever were suspected to have soft tissue infections were included in the study.

**Exclusion criteria:** Obese individuals, patients with extensive wound infection with raw areas and multiorgan dysfunction syndrome, and patients admitted to the intensive care unit were excluded from the study.

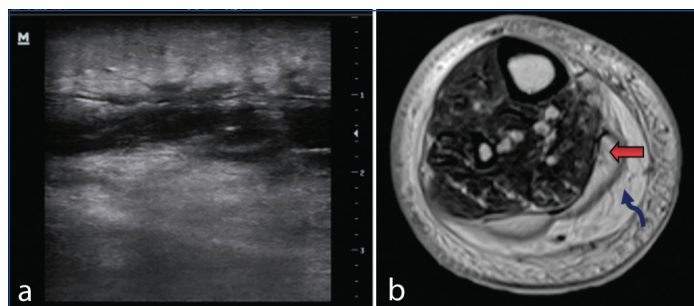
**Sample size calculation:** The study group consisted of 40 patients with a presumptive diagnosis by Yen ZS et al., in the diagnosis of NSTI which has a sensitivity of 88.2% [4].

## Study Procedure

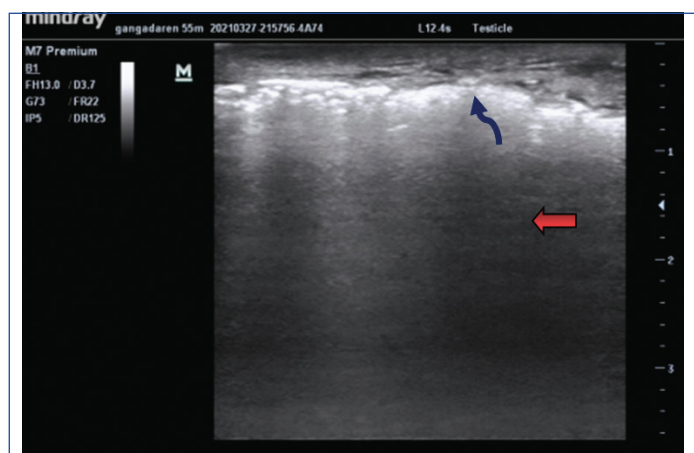
Initial diagnosis was made by both clinical and anatomical findings. Radiological investigations like plain radiographs and ultrasound were done to note gas formation in the subcutaneous layer. The arterial and venous doppler was done to rule out any vascular compromise. After doing a bedside ultrasound, 36 patients were found to be stable and shifted for MRI. Limited MRI sequences like Short Inversion Time Inversion Recovery (STIR), T1, T2, Fat-saturation (FatSat) were done for the 36 patients. MRI was the gold standard technique in the diagnosis of NSTI. USG and MRI findings were compared. The imaging findings taken into consideration for predicting NSTI include subcutaneous thickening, subcutaneous fluid collection, muscular oedema, and subcutaneous air pockets [Table/Fig-1a,b,2a,b]. Some cases showed minimal amount or foci of subcutaneous air pockets, where the imaging findings were not obscured. In few cases, the ultrasound findings were obscured due to reverberation artifact caused by diffuse or extensive air pockets [Table/Fig-3].



**[Table/Fig-1a,b]:** Ultrasonography (USG) and T2 axial sections of Magnetic Resonance Imaging (MRI) showing subcutaneous fat thickening (indicated by yellow colour thick arrow).



**[Table/Fig-2a,b]:** Ultrasonography (USG) and T2 axial sections of Magnetic Resonance Imaging (MRI) showing subcutaneous fat thickening (indicated by yellow colour thick arrow) and subcutaneous fluid collection (indicated by blue colour curved arrow).



**[Table/Fig-3]:** Ultrasonography (USG) image shows diffuse/extensive subcutaneous air pockets (indicated by blue colour curved arrow) which obscures the deeper structures (indicated by red colour thick arrow).

## STATISTICAL ANALYSIS

The collected data were analysed with International Business Machines Statistical Package for Social Sciences (IBM SPSS) Statistics for Windows, software version 23. (Armonk, NY: IBM Corp). To describe the data descriptive statistics frequency analysis, and

percentage analysis was used for categorical variables, and the mean and Standard Deviation (SD) were used for continuous variables. Sensitivity, specificity, Predictive Value (PPV) and Negative Predictive Value (NPV) were calculated. In all the above statistical tools the probability value of 0.05 was considered as statistically significant.

## RESULTS

The mean age of the study population was 52 years and the highest incidence was seen among 51-60 years with a distribution of 43% (17 patients) [Table/Fig-4]. The incidence in males was 62.5% (25 patients) and in females was 37.5% (15 patients). The lower limb was the most frequently affected site involving the 25 (62.5%) patients [Table/Fig-5]. Co-morbidities were present in 35 cases and the occurrence of the disease was commonly seen in the patients who had diabetic mellitus (n=21) followed by hypertension (n=14) [Table/Fig-6].

Age (years)	Frequency (n)	Percentage
30-40	5	13%
41-50	12	30%
51-60	17	43%
>60	6	15%

**[Table/Fig-4]:** Age distribution of the cases studied.

Gender	Region affected				Total (N=40) (n)
	Lower limb (n=25, 62.5%) (n (%))	Upper limb (n=7, 17.5%) (n (%))	Gluteal region (n=4, 10%) (n (%))	Perineum (n=4, 10%) (n (%))	
Female	11	3	1	0	15
Male	14	4	3	4	25

**[Table/Fig-5]:** Gender wise distribution of cases in relation to the site of involvement.

Co-morbidities	Frequency (n)	Percentage
DM, HTN	7	17.5%
Idiopathic	5	12.5%
DM, CVA	4	10.0%
CAD, CVA	3	7.5%
DM	2	5.0%
DM, CKD	2	5.0%
DM, HTN, CAD	2	5.0%
DM, Sepsis	2	5.0%
DM, Trauma	2	5.0%
HTN, TB	2	5.0%
HTN	2	5.0%
CAD	1	2.5%
CAD, Breast carcinoma	1	2.5%
CAD, HIV	1	2.5%
CAD, Trauma	1	2.5%
HIV	1	2.5%
HTN, CKD	1	2.5%
Trauma	1	2.5%

**[Table/Fig-6]:** Co-morbidities distribution among the cases.

DM: Diabetic mellitus; HTN: Hypertension; CKD: Chronic kidney disease; CAD: Coronary heart disease; CVA: Cerebrovascular accident; TB: Tuberculosis; HIV: Human immunodeficiency virus

In the present study, out of 40 patients, 38 patients had subcutaneous thickening, 28 patients had subcutaneous fluid collection, 20 patients had muscular oedema and 13 patients had subcutaneous air pockets. Out of 13 patients who had subcutaneous air pockets four people had extensive air pockets and the USG findings were obscured in that four cases due to reverberation artifacts caused by air pockets [Table/Fig-7]. The present study has a sensitivity of 93.5%, specificity of 80%, PPV of 96%, NPV of 66.67% and

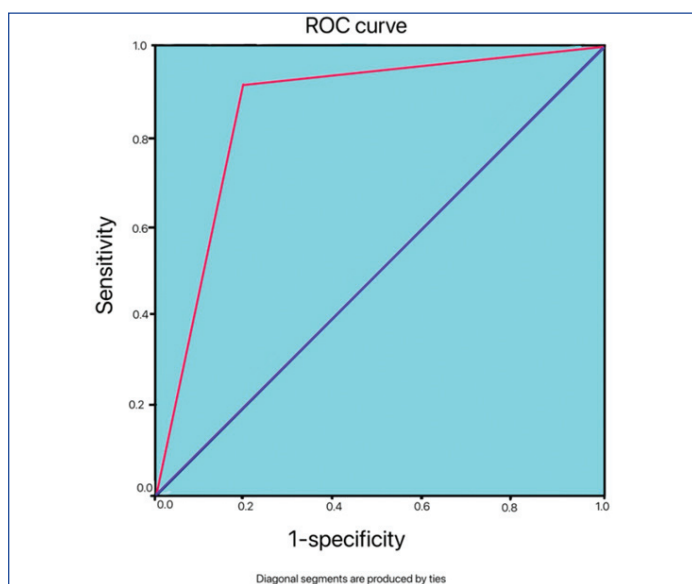
accuracy of 91.67% [Table/Fig-8]. The comparison of ultrasound in diagnosing NSTIs with MRI using Receiver Operating Characteristic curve (ROC curve) [Table/Fig-9], which showed the area under curve is 0.867, p-value=0.000042 with 95% Confidence Interval (CI) 0.782 to 0.952, which was highly statistically significance [Table/Fig-10].

USG findings	Present n (%)	Absent n (%)	Obscured by air pockets n (%)
Subcutaneous thickening	38 (95.0%)	-	2 (5.0%)
Subcutaneous oedema	28 (70.0%)	10 (25.0%)	2 (5.0%)
Muscular oedema	20 (50.0%)	16 (40.0%)	4 (10.0%)
Subcutaneous air pockets	Minimal- 9 (22.5%)	27 (67.5%)	
	Extensive- 4 (10.0%)		

[Table/Fig-7]: Distribution of the imaging features detected in ultrasound.

MRI for detecting necrotising fasciitis		Disease present (n)	Disease absent (n)	Total (n)	Sensitivity	93.5%
Ultrasound for detecting necrotising fasciitis	Disease present	29	1	30	PPV	96%
	Disease absent	2	4	6	NPV	66.67%
Total		31	5	36	Accuracy	91.67%

[Table/Fig-8]: Comparison of ultrasound with Magnetic Resonance Imaging (MRI) for detection of Necrotising Soft Tissue Infection (NSTI).



[Table/Fig-9]: Receiver Operating Characteristic curve (ROC curve).

Area under the curve (0.867)				
Area	Std. error	p-value	95% CI	
			LB	UB
0.867	0.0816	<b>0.000042</b>	0.782	0.952

[Table/Fig-10]: Area under the curve.

Chi-square test was used; p-value in bold font indicates statistically significant values

## DISCUSSION

The incidence of soft tissue infection increases with an increase in age with the highest incidence noted in those above 60 years of age [5]. In the present study, the overall incidence was higher in the older age group with the highest incidence among 51-60 years with a distribution of 43% (17 patients) followed by the age group between 41-50 years. This increase with age might be due to the higher occurrence of risk factors in the older age group.

The male population has a higher incidence of traumatic injury, also higher workplace hazards. Alcoholism among the male population is the predisposing factor for higher incidence. In the present study,

the incidence in males is 62.5% (25 patients), and in females is 37.5% (15 patients).

The prevalence of infection ranges between 40% and 60% in the case of diabetic patients [5]. In present study >50% of patients were found to be diabetic (n=21) followed by hypertension (n=14). Five (12.5%) patients donot have any co-morbidities or significant histories and, the cause is not found so the aetiology was considered idiopathic.

According to Anaya DA et al., the lower limb is the most common site for necrotising fasciitis. This is followed by the perineum and upper limb [6]. The least common site for necrotising fasciitis is the anterior abdominal wall. Some studies explained that necrotising fasciitis affects the perineal region commonly [7]. This variation might be due to differences in work patterns and hygiene among the population, whereas in western countries they follow higher safety precautions.

Plain radiographs identify gas or air pockets only in 16.9% of one series [8]. But this is a specific, not a sensitive finding (positive in fewer than 25% of cases). POCUS can improve the diagnostic accuracy for NSTI when used in combination with clinical evaluation. The main findings of NSTI by USG include "a cobblestone" appearance that occurs due to loss of normal architecture with irregularity and thickening of the fascia, abnormal subcutaneous fluid collections for atleast a thickness of 4 mm noted along the fascia which appears as hypoechogenic zones. In 2019 Lin CN et al., described the USG finding of fluid accumulation with a cut-off point of more than 2 mm thickness had the best accuracy (72.7%) for diagnosing necrotising fasciitis. Regarding prognosis, patients who had fluid accumulation along the deep fascia had a longer duration of hospital stay and were at risk of amputation or high mortality [4]. In advanced stages, the presence of air pockets in the subcutaneous tissues appears as hyperechogenic foci which have dirty acoustic shadowing posteriorly due to reverberation artifact [9,10]. In 2002 Yen ZS et al., collected data for 62 patients, of whom 17 (27.4%) were considered to suffer from necrotising fasciitis. In their study, the diagnosis of necrotising fasciitis by using USG has a sensitivity of 88.2%, a specificity of 93.3%, a PPV of 83.3%, a NPV of 95.4%, and an accuracy of 91.9% [3]. The present study has a sensitivity of 93.5%, specificity of 80%, PPV of 96%, NPV of 66.67%, and accuracy of 91.67%. Distinguishing necrotising infection from cellulitis or other causes of soft tissue oedema using USG is not always possible, especially in the case of deeper fascia involvement, because fascial thickening is noted in both cases. Findings that distinguish necrotising infection from cellulitis include irregularity of fascia and unusual fluid collection seen along the fascial plane [9]. Butcher CH et al., found that ultrasound has high sensitivity and specificity for detecting subcutaneous air (100% and 87.5%, respectively) [10]. The presence of subcutaneous fluid collection favours the diagnosis and the presence of subcutaneous air pockets confirms the diagnosis of necrotising fasciitis. A retrospective study by Parenti GC et al., 32 pathologically confirmed necrotising fasciitis presented that ultrasound showed changes in subcutaneous fat (87.5%), and muscle (46.8%), but did not disclose histologically apparent inflammation in the subcutaneous tissues (9.3%) or muscle (25%) in numerous cases [11]. In current cross-sectional study, ultrasound and MRI were done in 36 patients. Ultrasound detected the subcutaneous changes in 95% of patients and muscular changes were detected in 50% of the patients. MRI did not reveal disease in one patient who had subcutaneous fluid collection in ultrasound and considered as false positive (2.7%). But MRI detected the minimal fascial thickening in two patients, which had isolated subcutaneous thickening in ultrasound and were considered as false negative (5.5%). Ultrasound and MRI detected the muscular oedema and air pockets with true positive rate of 100%. Current study concluded that patients who had isolated subcutaneous thickening, detected in ultrasound exclude the diagnosis of necrotising fasciitis with

false negative rate of 5.5%. But when subcutaneous thickening associated with fluid collection favours the diagnosis and in addition muscle involvement, presence of air pockets confirms the diagnosis of necrotising fasciitis.

According to Malghem J et al., MRI is the gold standard with sensitivity and specificity varying according to the used criteria (the presence of air pockets has a specificity of 100% and the extensive involvement of the intermuscular fasciae has a sensitivity of 100%) [12]. In MRI, features that support necrotising fasciitis include fluid collections in the deep fascia and thickening appears as a hyperintense T2 signal within the muscles and enhancement after contrast administration. In the case of cellulitis, subcutaneous thickening, and fluid collection were demonstrated on T2-weighted images and involvement of subcutaneous tissue or superficial fascia shows contrast enhancement. According to Schmid MR et al., the sensitivity of MRI is 100% with a specificity of 86%. According to their criteria, they found 11 cases of necrotising fasciitis and six of cellulitis. MRI identified all 11 cases of necrotising fasciitis correctly, and the findings were compared with the surgical findings. One case of cellulitis was diagnosed as necrotising fasciitis by MRI and turned into a false positive case [13]. Arslan A et al., have argued that in early cases of necrotising fasciitis, MRI might not show fascial involvement [14].

This study shows the utility of bedside ultrasound for the decision making process where an early diagnosis is important for a disease. The information obtained from imaging should always be combined with clinical features, as it has a low sensitivity. This study also aids differentiation between the necrotising infection from cellulitis and enables appropriate treatment for the condition, thereby reducing unnecessary surgical intervention. The present study showed that the sensitivity and specificity of the POCUS are as good as MRI in diagnosing necrotising fasciitis. In countries with a low resource setting, where access to computed tomography and MRI may be difficult and particularly in a rural set-up, the presence of USG would be very helpful in easy bedside diagnosis and too cost-effective. In addition, very minimal training is required for acquiring images and interpreting the same.

### Limitation(s)

Ultrasonography examination is an operator dependent technique and the handling of the probe varies from person to person. Diffuse subcutaneous air pockets in the USG examination obscure the internal findings. Hyperechogenic inflamed subcutaneous tissue

reflects most of the ultrasound rays so evaluation of the deeper structures will be difficult. The deeper extent of the infections and underlying bony involvement could not be evaluated.

### CONCLUSION(S)

This study combines clinical evaluation with POCUS to show the characteristics that favour NSTI, such as the presence of gas in the tissue and subcutaneous fluid collection, which enables a quicker initiation of appropriate treatment including surgical debridement, without transporting the patient to a time-consuming examination like MRI, that could otherwise delay the diagnosis and the treatment.

### REFERENCES

- [1] Levine EG, Manders SM. Life-threatening necrotizing fasciitis. *Clin Dermatol.* 2005;23:144-47. Doi: 10.1016/j.clindermatol.2004.06.014.
- [2] Hefny AF, Eid HO, Al-Hussona M, Idris KM, Abu-Zidan FM. Necrotizing fasciitis: a challenging diagnosis. *Eur J Emerg Med.* 2007;14(1):50-52.
- [3] Yen ZS, Wang HP, Ma HM, Chen SC, Chen WJ. Ultrasonographic screening of clinically-suspected necrotizing fasciitis. *Acad Emerg Med.* 2002;9(12):1448-51. Doi: 10.1197/aemj.9.12.1448.
- [4] Lin CN, Hsiao CT, Chang CP, Huang TY, Hsiao KY, Chen YC, et al. The relationship between fluid accumulation in ultrasonography and the diagnosis and prognosis of patients with necrotizing fasciitis. *Ultrasound Med Biol.* 2019;45(7):1545-50.
- [5] Goh T, Goh LG, Ang CH, Wong CH. Early diagnosis of necrotizing fasciitis. *Br J Surg.* 2014;101:119-25. Doi:10.1002/bjs.93715.
- [6] Anaya DA, McMahon K, Nathens AB. Predictors of mortality and limb loss in necrotizing soft tissue infections. *Arch Surg.* 2005;140:151-57. Doi:10.1001/archsurg.140.2.151.
- [7] Morua AG, Lopez JA, Garcia JD, Montelongo RM, Guerra LS. Fournier's gangrene: our experience in 5 years, bibliographic review and assessment of the Fournier's gangrene severity index. *Arch Esp Urol.* 2009;62:532-40.
- [8] Wong CH, Chang HC, Pasupathy S, Khin LW, Tan JL, Low CO. Necrotizing fasciitis: clinical presentation, microbiology, and determinants of mortality. *J Bone Joint Surgery Am.* 2003;85-A(8):1454-60.
- [9] Tsai CC, Lai CS, Yu ML, Chou CK, Lin SD. Early diagnosis of necrotizing fasciitis by utilization of ultrasonography. *Kaohsiung J Med Sci.* 1996;12(4):235-40.
- [10] Butcher CH, Dooley RW, Levitov AB. Detection of subcutaneous and intramuscular air with sonography: a sensitive and specific modality. *J Ultrasound Med.* 2011;30:791-95.
- [11] Parenti GC, Marri C, Calandra G, Morisi C, Zabberoni W. Necrotizing fasciitis of soft tissues: role of diagnostic imaging and review of the literature. *Radiol Med.* 2000;99:334-39.
- [12] Malghem J, Lecouvet FE, Omoumi P, Maldague BE, Vande Berg BC. Necrotizing fasciitis: contribution and limitations of diagnostic imaging. *Joint Bone Spine.* 2013;80(2):146-54.
- [13] Schmid MR, Kossmann T, Duewell S. Differentiation of necrotizing fasciitis and cellulitis using MR imaging. *AJR Am J Roentgenol.* 1998;170(3):615-20.
- [14] Arslan A, Pierre-Jerome C, Borthne A. Necrotizing fasciitis: unreliable MRI findings in the preoperative diagnosis. *Eur J Radiol.* 2000;36(3):139-43.

#### PARTICULARS OF CONTRIBUTORS:

1. Professor and Head, Department of Radiodiagnosis, Stanley Medical College, Chennai, Tamil Nadu, India.
2. Assistant Professor, Department of Radiodiagnosis, Barnard Institute of Radiodiagnosis, Chennai, Tamil Nadu, India.
3. Professor, Department of Radiodiagnosis, Stanley Medical College, Chennai, Tamil Nadu, India.
4. Assistant Professor, Department of Radiodiagnosis, Stanley Medical College, Chennai, Tamil Nadu, India.
5. Professor, Department of Radiodiagnosis, Stanley Medical College, Chennai, Tamil Nadu, India.
6. Junior Resident, Department of Radiodiagnosis, Stanley Medical College, Chennai, Tamil Nadu, India.

#### NAME, ADDRESS, E-MAIL ID OF THE CORRESPONDING AUTHOR:

Dr. Bharathi Priya Raju,  
Assistant Professor, Department of Radiodiagnosis, Government Stanley Medical College, Old Jail Road, Old Washermanpet, Chennai, Tamil Nadu, India.  
E-mail: 82bharathi82@gmail.com

#### AUTHOR DECLARATION:

- Financial or Other Competing Interests: None
- Was Ethics Committee Approval obtained for this study? Yes
- Was informed consent obtained from the subjects involved in the study? Yes
- For any images presented appropriate consent has been obtained from the subjects. Yes

#### PLAGIARISM CHECKING METHODS: [Jain H et al.]

- Plagiarism X-checker: Dec 23, 2023
- Manual Googling: Mar 10, 2023
- iThenticate Software: Mar 13, 2023 (17%)

#### ETYMOLOGY: Author Origin

Date of Submission: **Dec 22, 2022**  
Date of Peer Review: **Feb 22, 2023**  
Date of Acceptance: **Mar 14, 2023**  
Date of Publishing: **Jul 01, 2023**